

AMSER Case of the Month

January 2023

14yo female presents with intermittent, tender
bilateral axillary palpable masses

Emily Schultz, MS4

Cooper Medical School of Rowan University

Samantha Snyder, DO

Cooper University Health Care

Pauline Germaine, DO

Cooper University Health Care



Patient Presentation

- HPI: 14yo female presents with L>R, mildly tender, nonpruritic axillary masses, with similar intermittent episodes over last 9 months, with symptomatic relief following oral antibiotics.
 - Denies drainage, bleeding, overlying skin changes, trauma, or new topical exposures.
 - No recent sick contacts.
- PMHx: Allergic rhinitis
- Meds: None
- Allergies: NKA
- Vitals: 116/62mmHg; 75bpm; 97.6F
- Physical Exam: NAD. Skin warm and well perfused, no visible rashes or bruising.
 - Left axilla: 2-3 Non-tender, discrete oblong-shaped masses. No erythema or fluctuance.
 - Right axilla: One non-tender discrete mass. No erythema or fluctuance.

Pertinent Labs

- N/A

What Imaging Should We Order?

ACR Appropriateness Criteria: Imaging of the Axilla

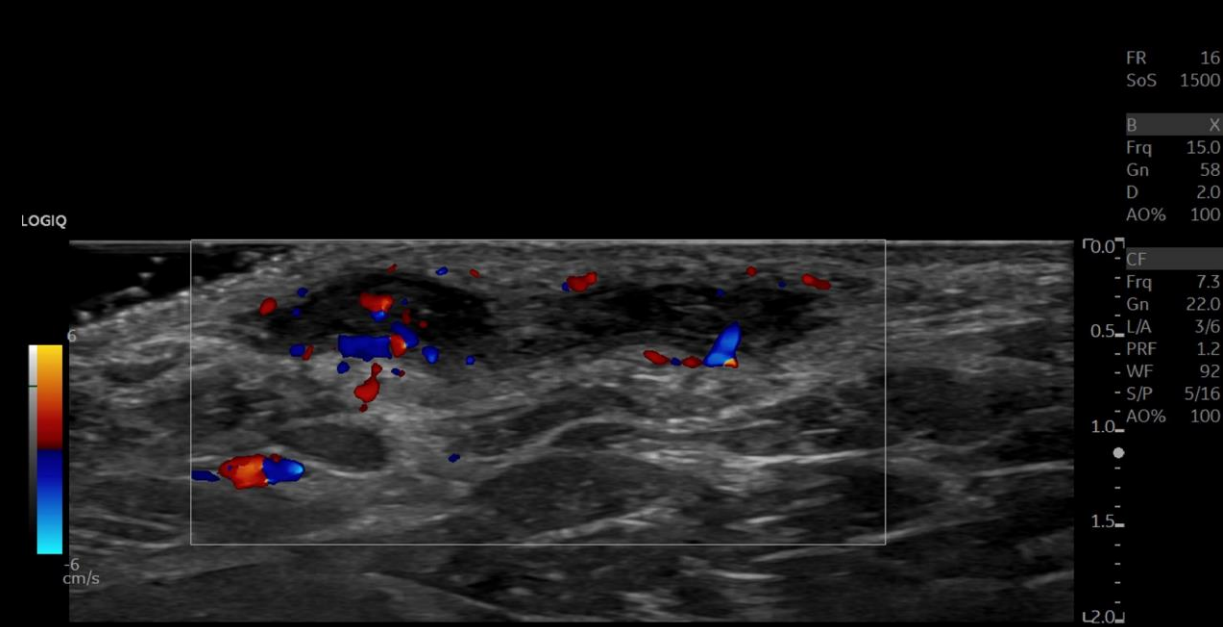
Variant 1:

Female. New palpable, unilateral, axillary lump. Initial imaging of the axilla.

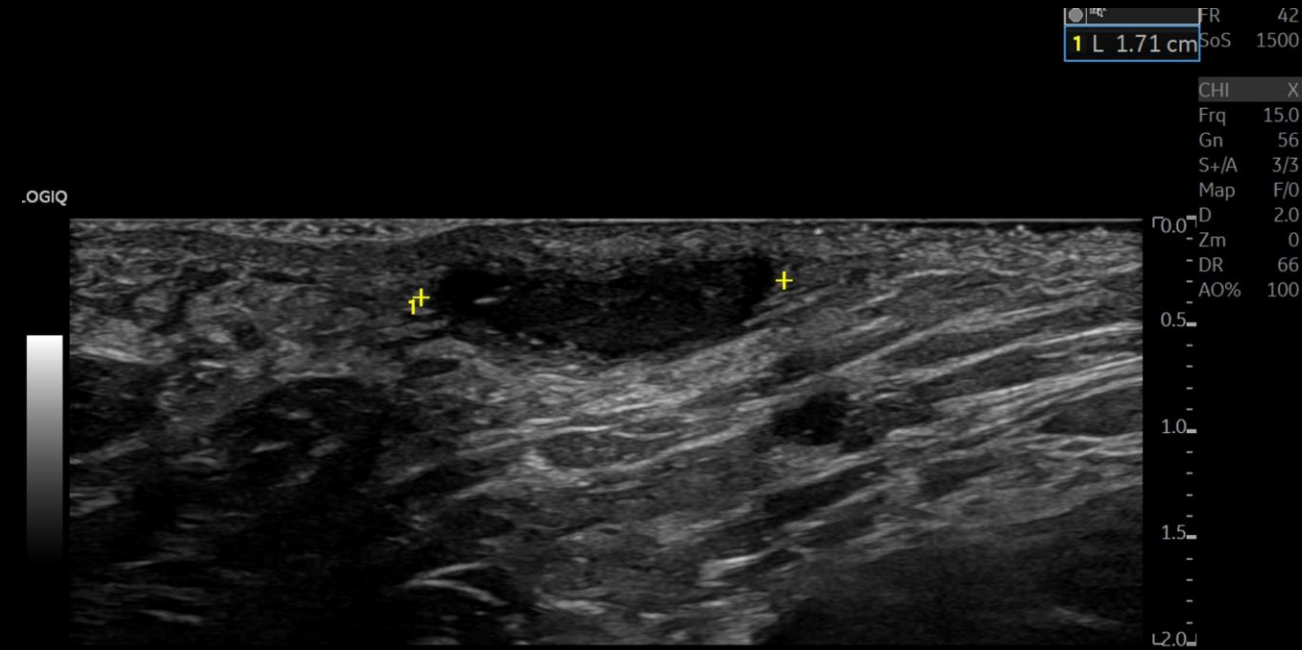
Procedure	Appropriateness Category	Relative Radiation Level
US axilla	Usually Appropriate	0
Digital breast tomosynthesis diagnostic	May Be Appropriate	☢☢
Mammography diagnostic	May Be Appropriate	☢☢
MRI breast without and with IV contrast	Usually Not Appropriate	0
MRI breast without IV contrast	Usually Not Appropriate	0
Sestamibi MBI	Usually Not Appropriate	☢☢☢
CT chest abdomen pelvis with IV contrast	Usually Not Appropriate	☢☢☢☢
CT chest abdomen pelvis without and with IV contrast	Usually Not Appropriate	☢☢☢☢
CT chest abdomen pelvis without IV contrast	Usually Not Appropriate	☢☢☢☢
FDG-PET/CT skull base to mid-thigh	Usually Not Appropriate	☢☢☢☢

← This test was ordered by the provider

Findings

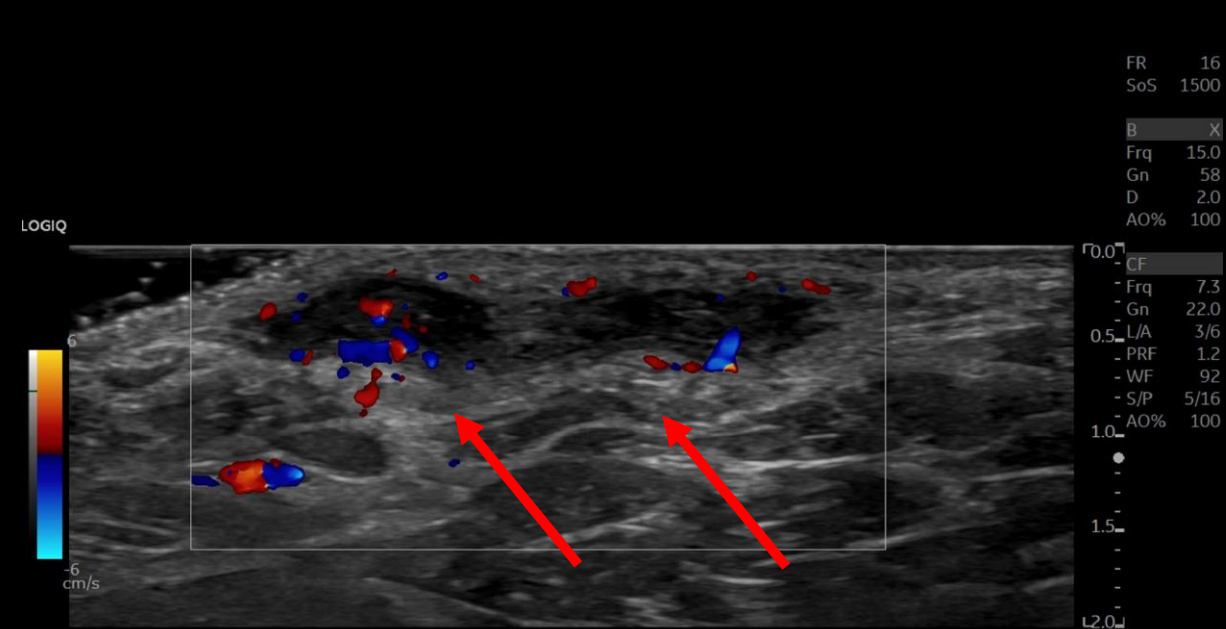


LT AXILLA LONG PALP

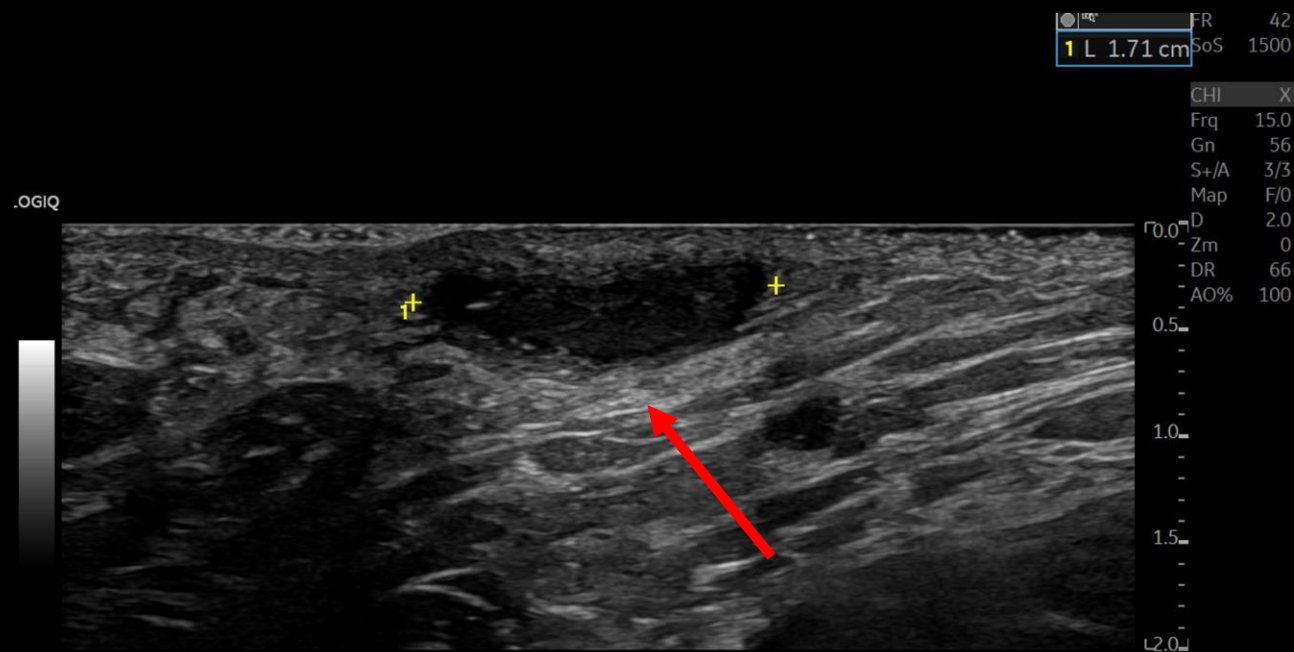


LT AXILLA TRANS PALP

Findings (labeled)



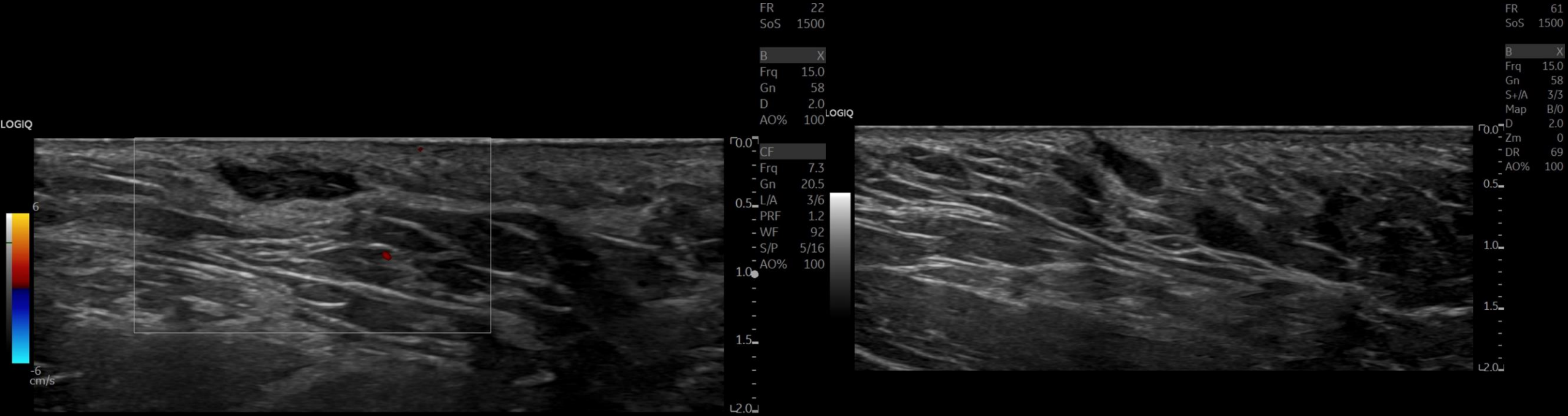
LT AXILLA LONG PALP



LT AXILLA TRANS PALP

Complicated fluid collection with increased peripheral vascularity (red arrows) immediately deep to the dermis, slightly raising the skin. No sinus tract extending to the surface is visible.

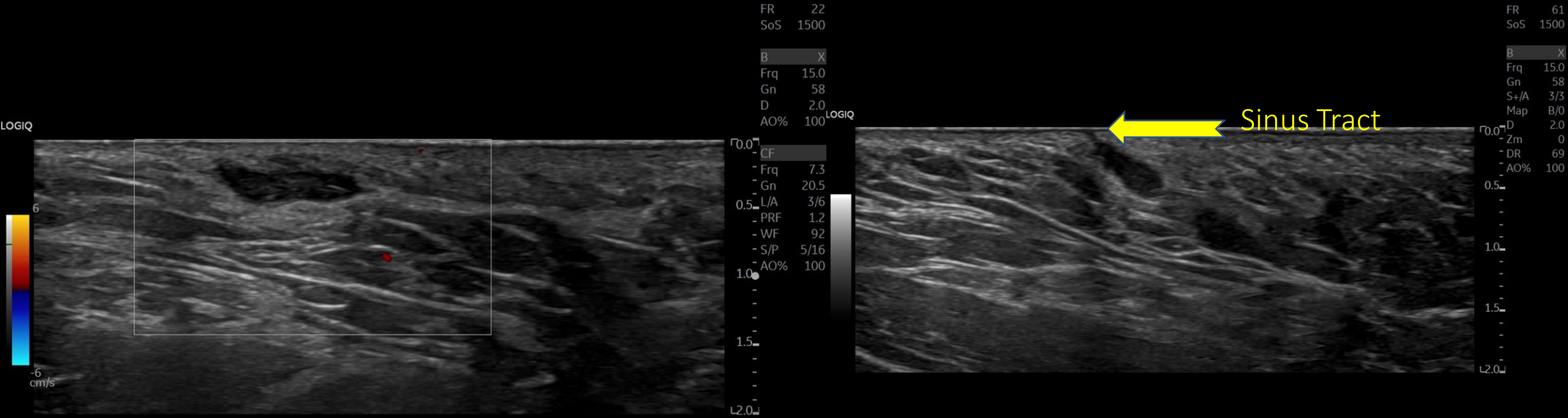
Findings



RT AXILLA TRANS

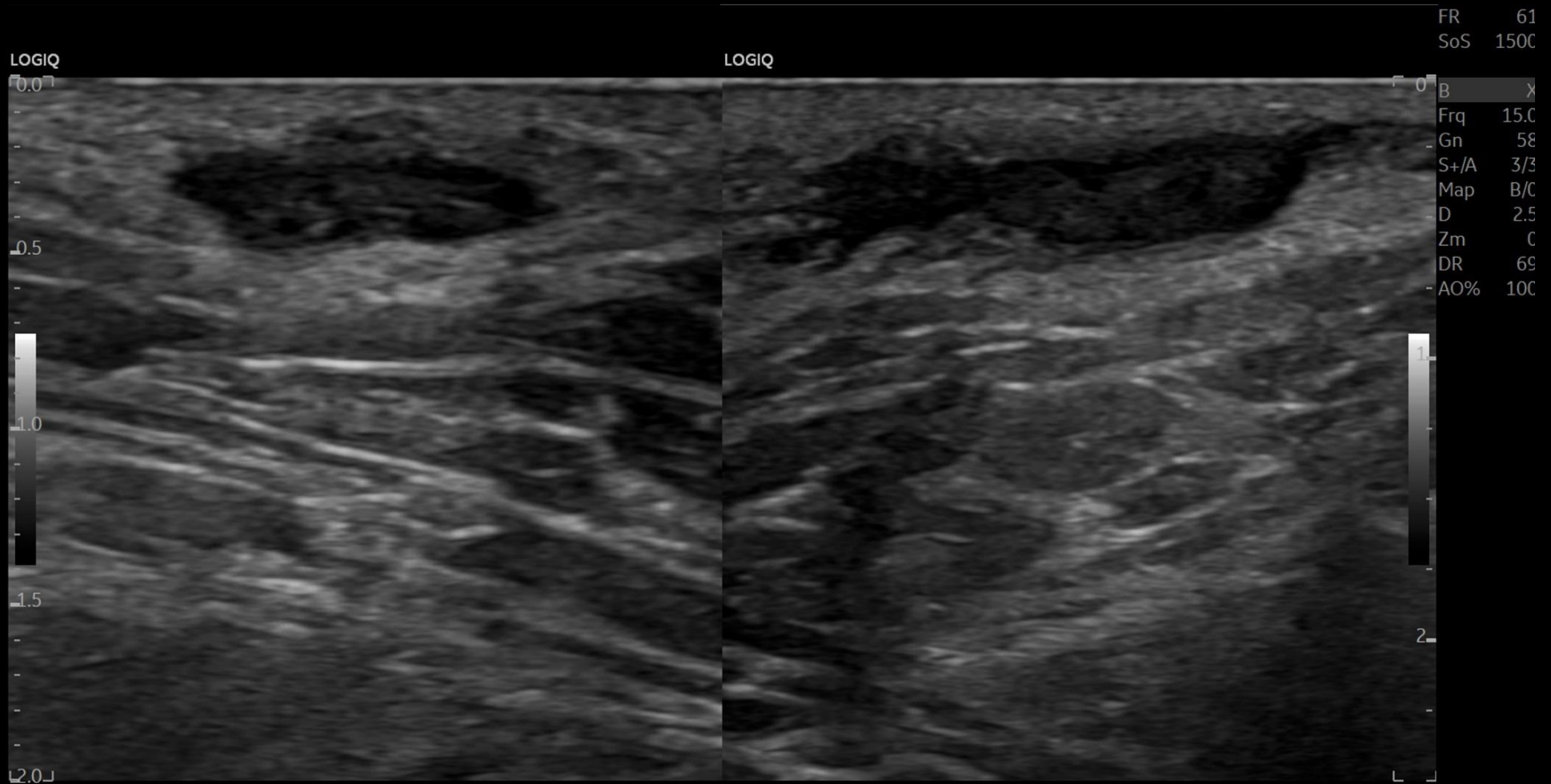
RT AXILLA LONG

Findings (labeled)



Complicated fluid collection in the right axilla without increased vascularity on Color Doppler assessment. Linear hypoechoic tract extends to the skin surface, consistent with sinus tract.

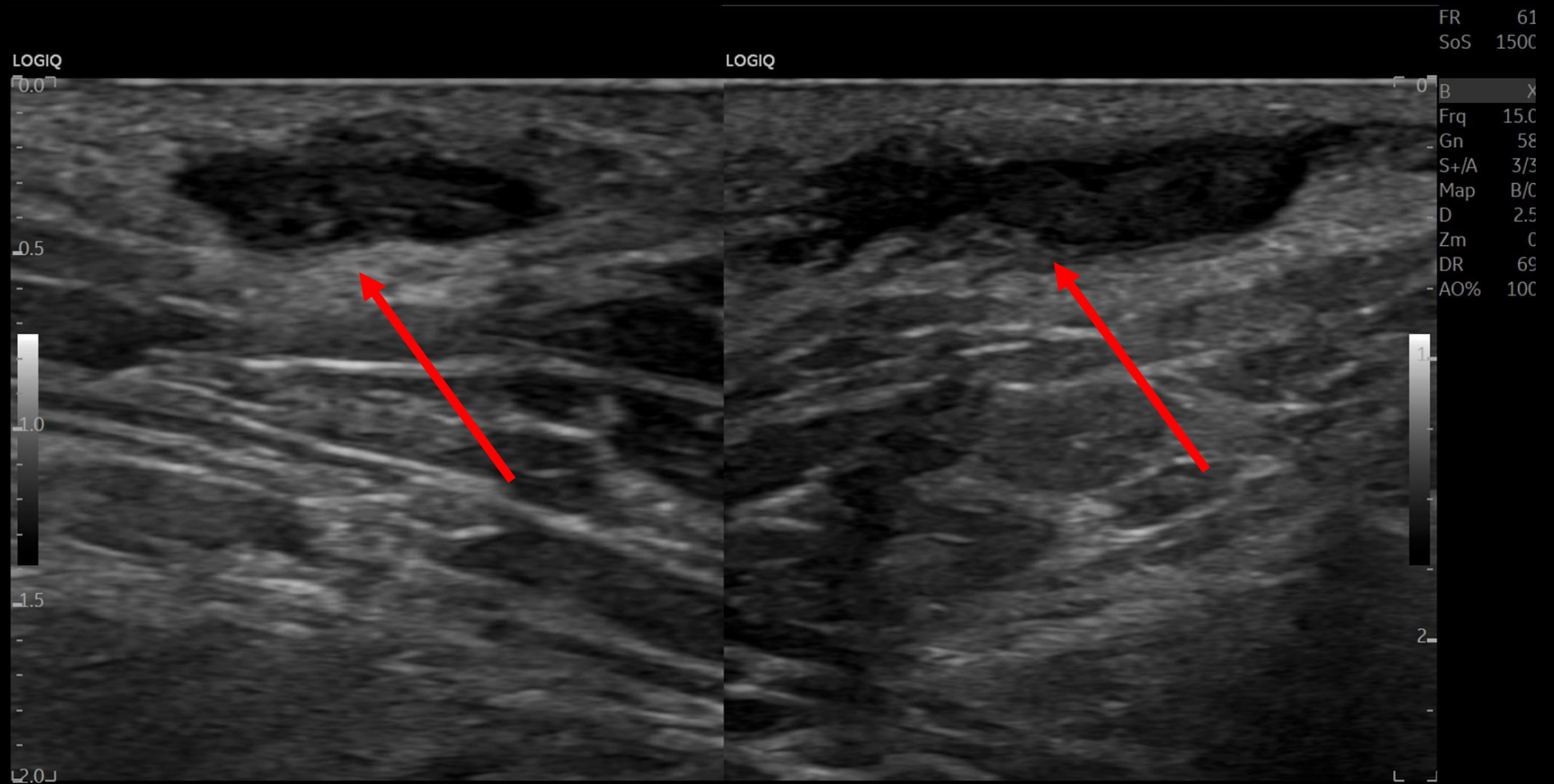
Findings



RT AXILLA LONG

LT AXILLA PALP

Findings (labeled):



RT AXILLA LONG

LT AXILLA PALP

Both axillary regions have similar areas of involvement

Final Dx:

Hidradenitis Suppurativa

Hidradenitis Suppurativa (HS)

- **Definition:** HS, also referred as acne inversus, is a chronic inflammatory skin condition involving the follicular portion of folliculopilosebaceous units.
- **Etiology:** Exact etiology remains unclear. Clinical manifestations thought to result from follicular occlusion, rupture and resultant chemotactic inflammatory response.
 - Additional theories:
 - Immunological abnormalities (elevated cytokines etc.)
 - Antimicrobial peptides abnormalities
 - Abnormal secretion of apocrine sweat glands or deficient sebaceous glands
 - Abnormal epidermal invaginations
- Associated with genetics, obesity, smoking, mechanical stress, hormone fluctuations, & controversial role of bacteria.
- **DDx:** Follicular pyodermas (folliculitis, furuncles, carbuncles) v acne vulgaris v enlarged lymph node; intergluteal pilonidal disease v Crohn Disease; cat scratch fever (lymphoreticulosis) v sporotrichosis v bubonic plague (*Y. pestis*) v granuloma inguinale.

Hidradenitis Suppurativa: Diagnosis

- **Clinical Presentation:**
 - **Typical Lesions:**
 - Initial painful, inflamed nodule &/or abscess formation
 - Prolonged skin tunnels/sinus tracts formation
 - Comedones appear in longstanding HS
 - Scarring appearance can vary (acneiform scars, fibrotic bands, plaques)
 - **Primary Sites of Involvement:** Intertriginous skin areas of the axillary, groin, perianal, perineal, & inframammary regions.
 - **Relapses & Chronicity:** Recurrence of inflammatory nodules, skin tunnels, & scarring.
- **Hurley Staging:**
 - Stage 1: Abscess formation without tracts/scars
 - Stage 2: Recurrent abscesses with tracts/scars, either single or separated lesions
 - Stage 3: Diffuse involvement with interconnected tracts and abscesses
- **Imaging:**
 - Ultrasound: Assess subclinical extent of disease, particularly skin tunnels
 - MRI: Evaluate extent of anogenital disease

Hidradenitis Suppurativa: Management

- **Goals:** Minimize discomfort, decrease reoccurrence and prevent progression.
- **General Interventions:** Pain management; wound care; smoking cessation and weight loss.
- **Stage 1:**
 - Initial: Topical clindamycin +/- PO: tetracyclines; antiandrogenic agents (OCPs, spironolactone); metformin
 - Refractory: PO clindamycin/rifampin; dapsona; retinoids
- **Stage 2/3:**
 - Initial: PO tetracyclines or clindamycin/rifampin +/- antiandrogenic agents or metformin
 - If fail: PO retinoids; dapsona; TNF inhibitors (adalimumab & infliximab)
 - Severe/Refractory: Wide excision

References:

- Ballard K., & Shuman V.L. (2021). Hidradenitis Suppurativa. *StatPearls*. Retrieved September 14, 2022 from <https://www.ncbi.nlm.nih.gov/books/NBK534867/>
- Ingram, J.R. (2022). Hidradenitis Suppurativa: Pathogenesis, clinical features, and diagnosis. *UpToDate*. Retrieved September 14, 2022 from https://www.uptodate.com/contents/hidradenitis-suppurativa-pathogenesis-clinical-features-and-diagnosis?search=hidradenitis%20suppurativa&source=search_result&selectedTitle=2~76&usage_type=default&display_rank=2
- Ingram, J.R. (2022). Hidradenitis Suppurativa: Management. *UpToDate*. Retrieved September 14, 2022 from https://www.uptodate.com/contents/hidradenitis-suppurativa-management?search=hidradenitis%20suppurativa&source=search_result&selectedTitle=1~76&usage_type=default&display_rank=1
- Wortsman, X., & Jemec, G. B. (2007). Real-time compound imaging ultrasound of hidradenitis suppurativa. *Dermatologic surgery : official publication for American Society for Dermatologic Surgery [et al.]*, 33(11), 1340–1342. <https://doi.org/10.1111/j.1524-4725.2007.33286.x>
- Elkin, K., Daveluy, S., & Avanaki, K. (2020). Hidradenitis suppurativa: Current understanding, diagnostic and surgical challenges, and developments in ultrasound application. *Skin Research and Technology*, 26(1), 11-19.