

# AMSER Rad Path Case of the Month:

67-year-old female presenting with hypertension and flank pain

Esther Kim, MS4

Drexel University College of Medicine

Lydia Du, PGY1

Dr. Goutham Vemana, MD

Dr. Janice Ahn, MD

Dr. Matthew Hartman, MD

Allegheny Health Network



# Patient Presentation

HPI: 67-year-old female with a hx of hypertension and insulin-dependent diabetes presents to the ED with several months of intermittent flank pain radiating to her left abdomen. She had one episode of N/V along with diarrhea associated with the pain. She endorses being told of having blood in her urine when she visited the doctor several months prior, but no testing was done at that time. She denies fever, chills, dysuria, or hematuria.

PE: Tenderness in the left upper and lower quadrants

What Imaging Should We Order?

# ACR Appropriateness Guidelines:

**Clinical Condition:** Acute Onset Flank Pain—Suspicion of Stone Disease (Urolithiasis)

**Variant 1:** Suspicion of stone disease.

Radiologic Procedure	Rating	Comments	RRL*
CT abdomen and pelvis without IV contrast	8	Reduced-dose techniques are preferred.	⊕⊕⊕
CT abdomen and pelvis without and with IV contrast	6	This procedure is indicated if CT without contrast does not explain pain or reveals an abnormality that should be further assessed with contrast (eg, stone versus phleboliths).	⊕⊕⊕⊕
US color Doppler kidneys and bladder retroperitoneal	6		○
Radiography intravenous urography	4		⊕⊕⊕
MRI abdomen and pelvis without IV contrast	4	MR urography.	○
MRI abdomen and pelvis without and with IV contrast	4	MR urography.	○
X-ray abdomen and pelvis (KUB)	3	This procedure can be performed with US as an alternative to NCCT.	⊕⊕
CT abdomen and pelvis with IV contrast	2		⊕⊕⊕

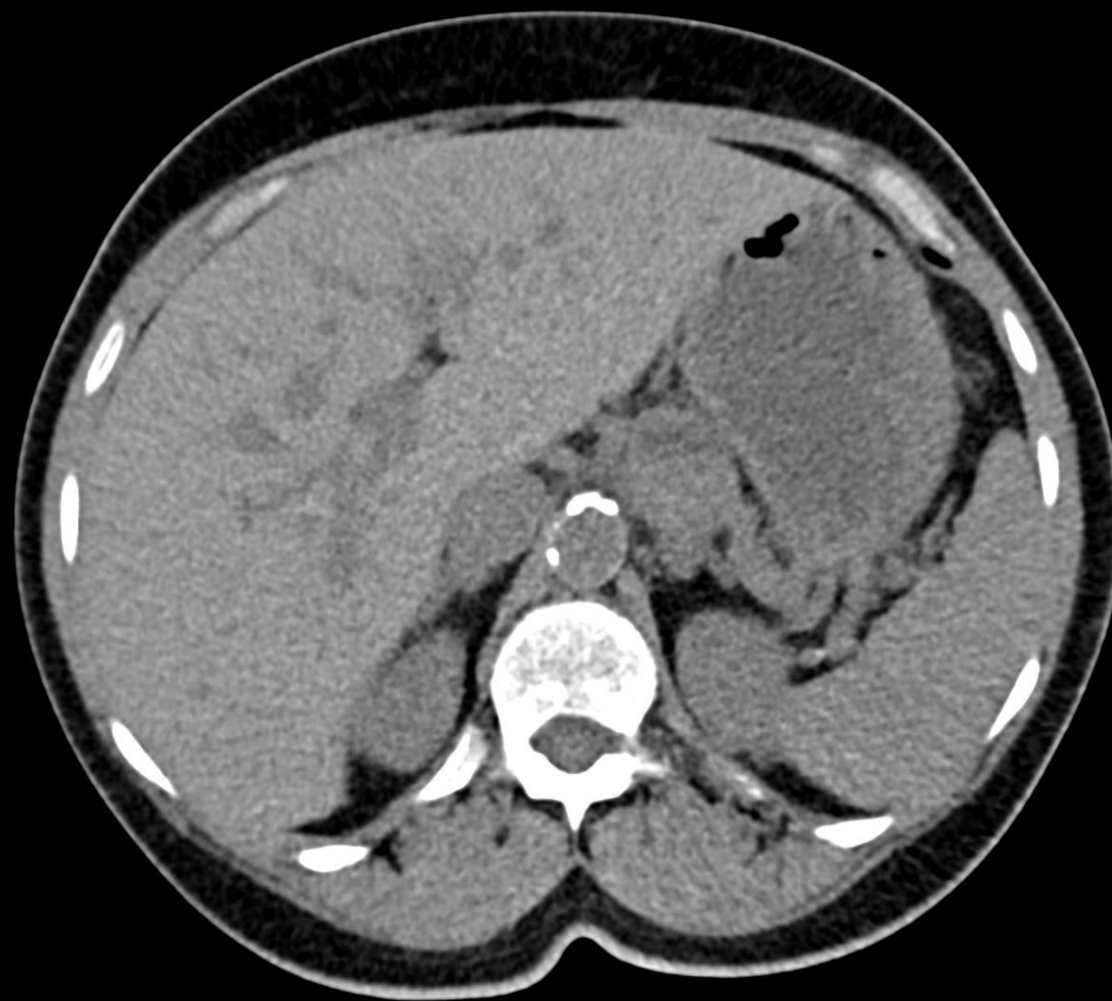
**Rating Scale:** 1,2,3 Usually not appropriate; 4,5,6 May be appropriate; 7,8,9 Usually appropriate

**\*Relative Radiation Level**

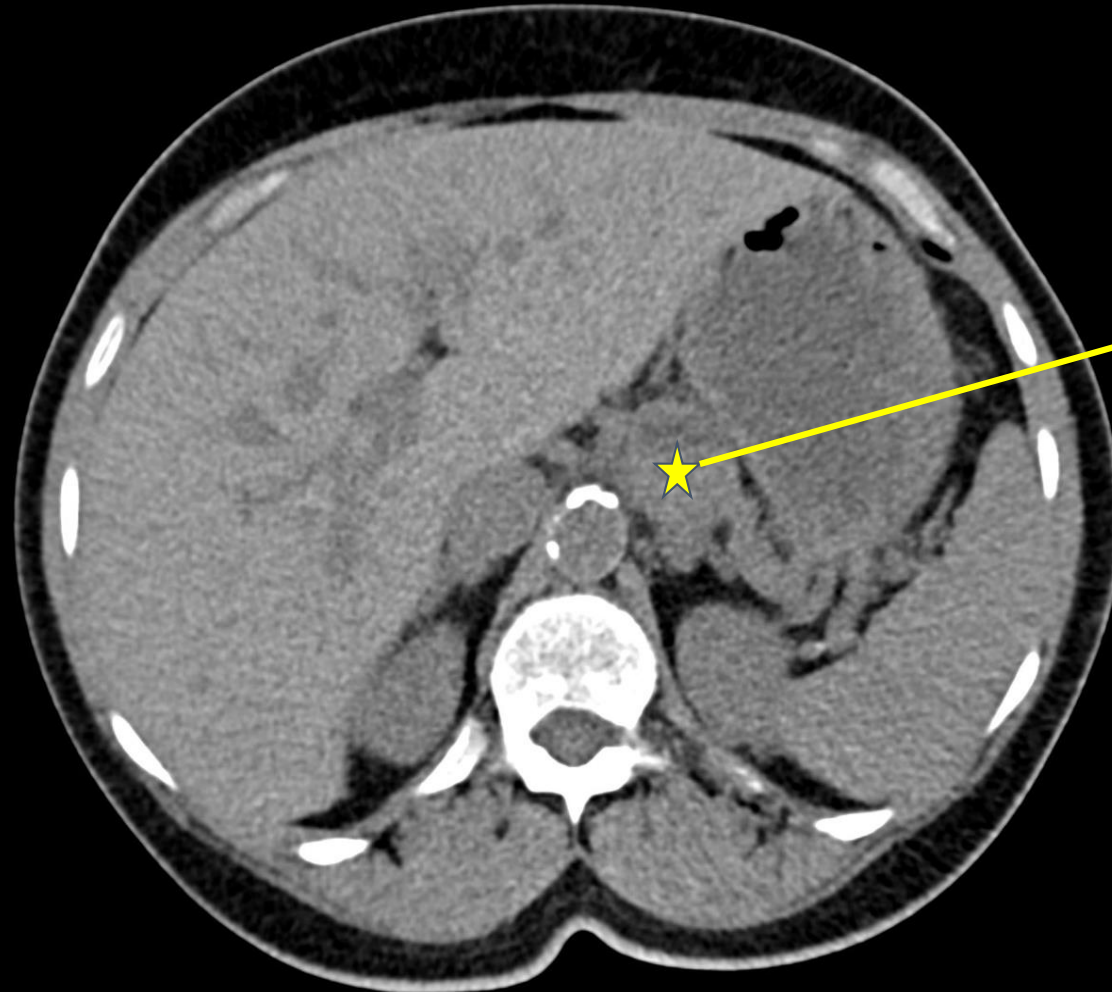
Ordered by  
the ER  
physician



CT A/P w/o contrast (unlabeled)



# CT A/P w/o contrast (labeled)



Abnormal mass in the gastro-hepatic ligament measuring 3 cm. Could be related to an abnormal lymph node/malignancy or could be an adrenal nodule

No findings of nephrolithiasis

Axial view, non-contrast

What Additional Imaging Was Ordered?

# ACR Appropriateness Guidelines:

## Variant 3:

**Indeterminate adrenal mass, greater than 2 cm and less than 4 cm on initial imaging. No diagnostic benign imaging features. No history of malignancy. Adrenal specific imaging.**

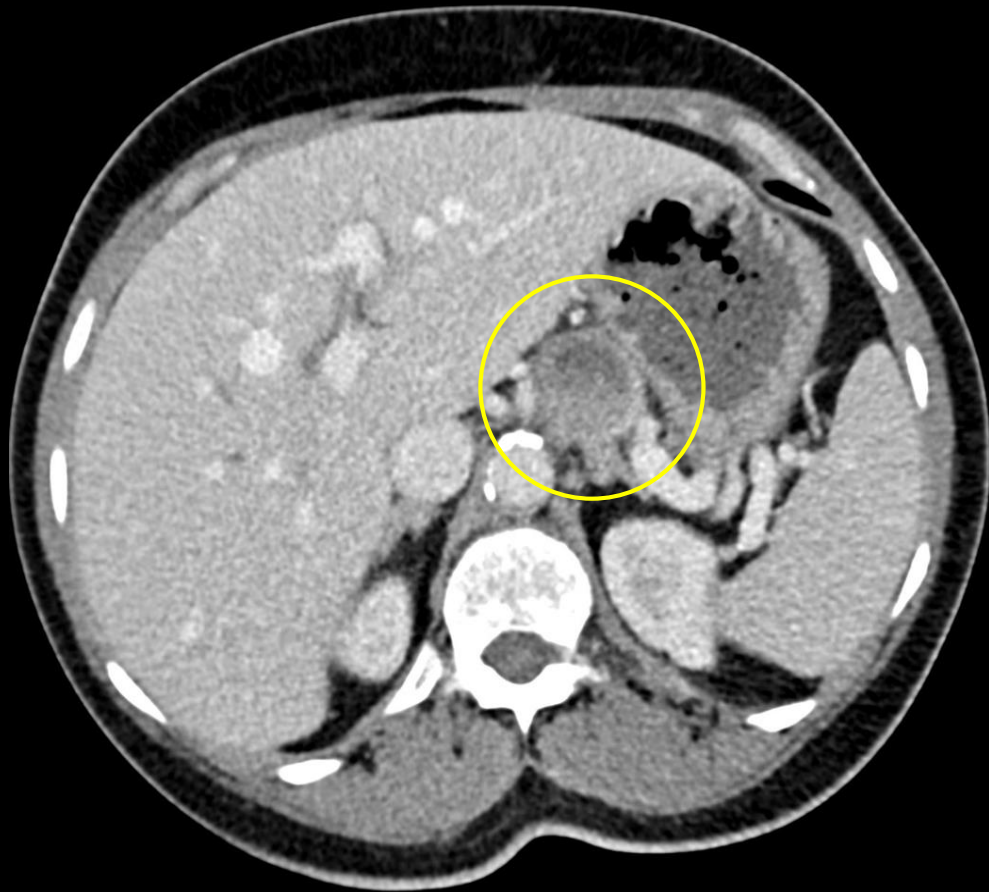Procedure	Appropriateness Category	Relative Radiation Level
MRI abdomen without and with IV contrast	Usually Appropriate	○
MRI abdomen without IV contrast	Usually Appropriate	○
CT abdomen without and with IV contrast	Usually Appropriate	☢☢☢☢
CT abdomen without IV contrast	May Be Appropriate	☢☢☢
Image-guided biopsy adrenal gland	Usually Not Appropriate	Varies
CT abdomen with IV contrast	Usually Not Appropriate	☢☢☢
FDG-PET/CT skull base to mid-thigh	Usually Not Appropriate	☢☢☢☢

Ordered by  
the ER  
physician



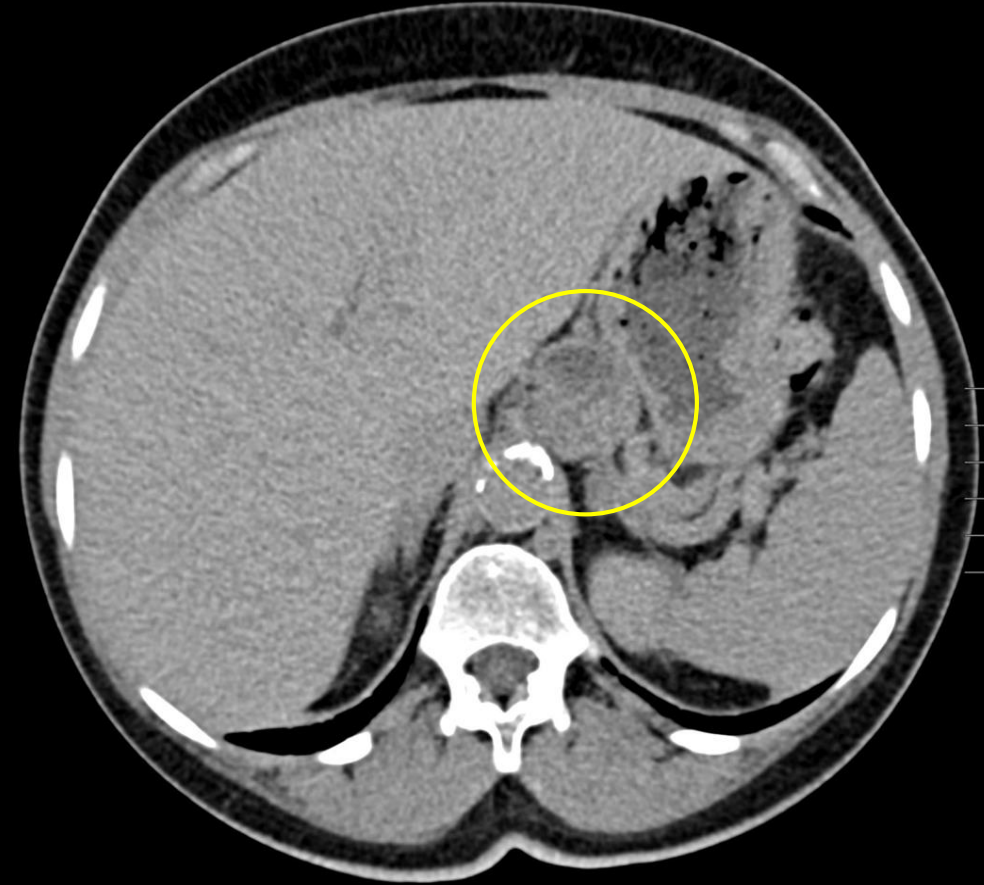


# CT A/P w/ contrast (labeled)



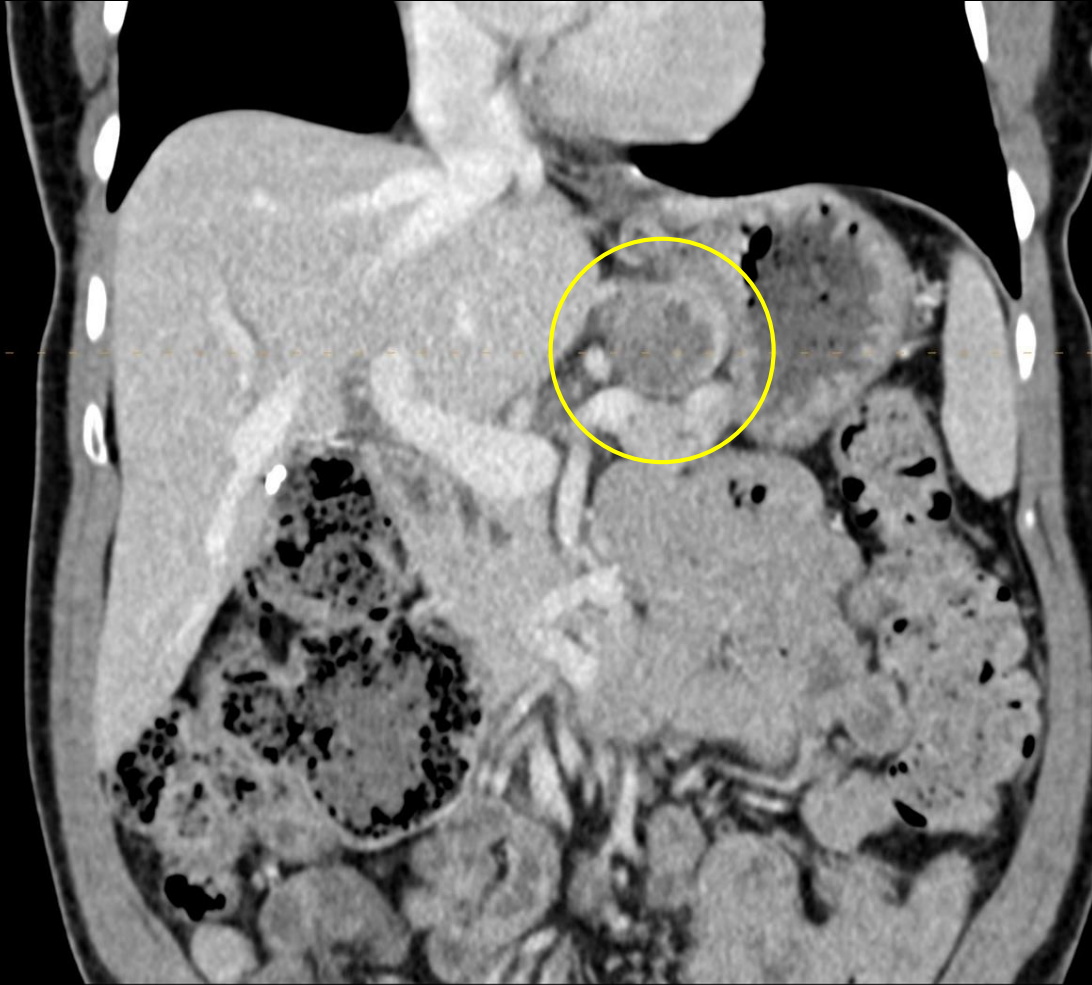
Axial view, Portal venous phase

2.9 cm heterogeneous mass with mixed densities favored to arise from the L adrenal gland rather than represent an enlarged lymph node



Axial view, Delayed phase

# CT A/P w/ contrast (labeled)



2.9 cm heterogeneous  
mass with mixed  
densities

Coronal view, Portal venous phase

# Pertinent Follow-up Labs

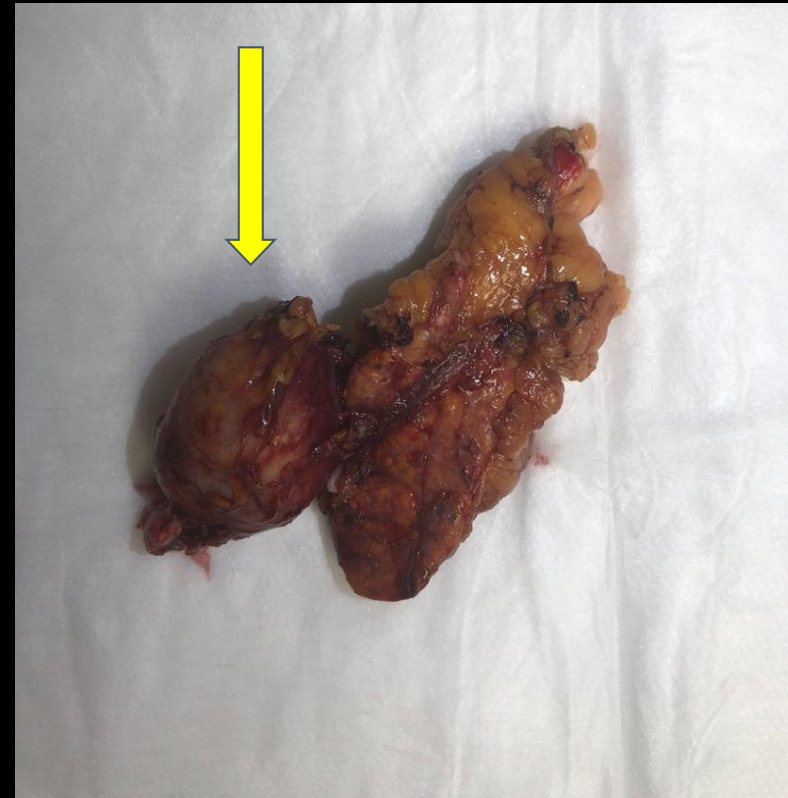
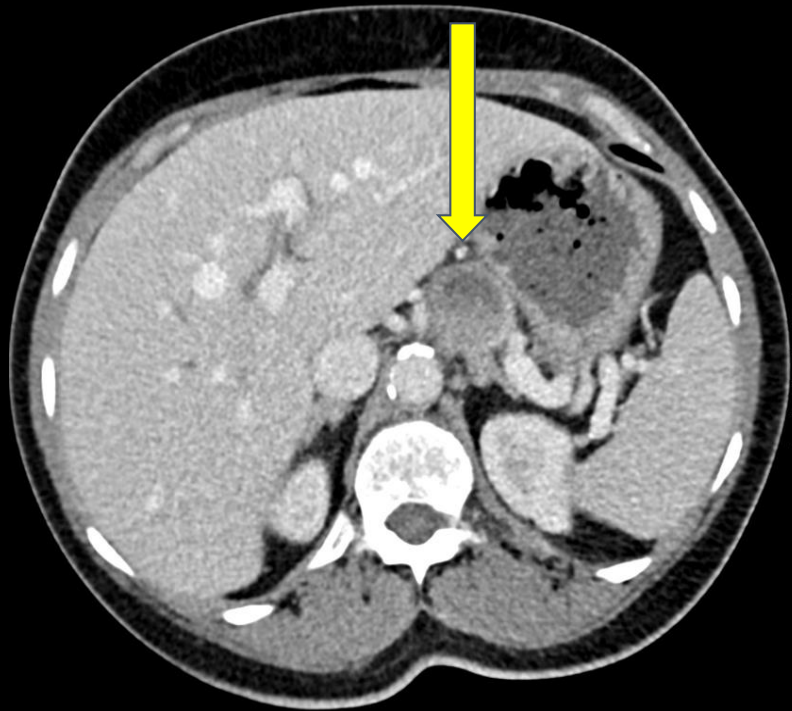
- Plasma free metanephrines: 338.3 pg/mL (ref: 0-88 pg/mL)
- Plasma free normetanephrines: 444 pg/mL (ref: 0-285.2 pg/mL)

# Differential diagnoses based on imaging:

- Pheochromocytoma/Paraganglioma
- Metastases
- Adrenal cortical adenoma
- Enlarged lymph node

# Gross Findings

s/p robotic assisted laparoscopic adrenalectomy



The mass (yellow arrow) appears to be separate from adjacent adrenal gland on the external surface



Normal appearing  
adrenal gland with  
perirenal fat

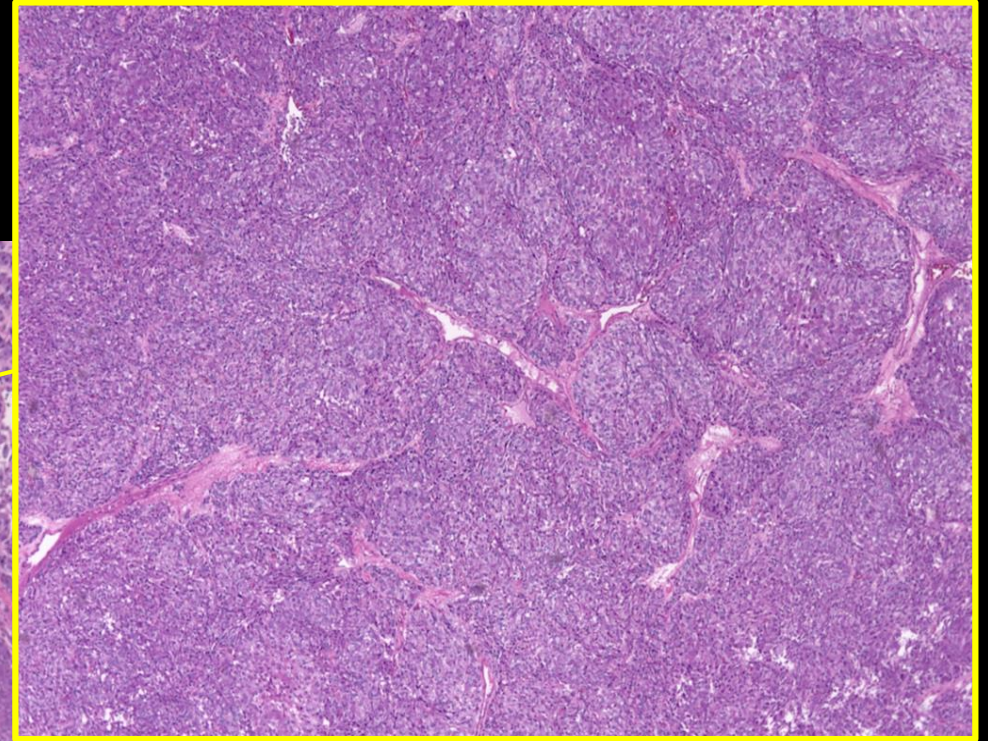


Mass measures  
3 x 2.5 x 2.5 cm  
and inked in  
green

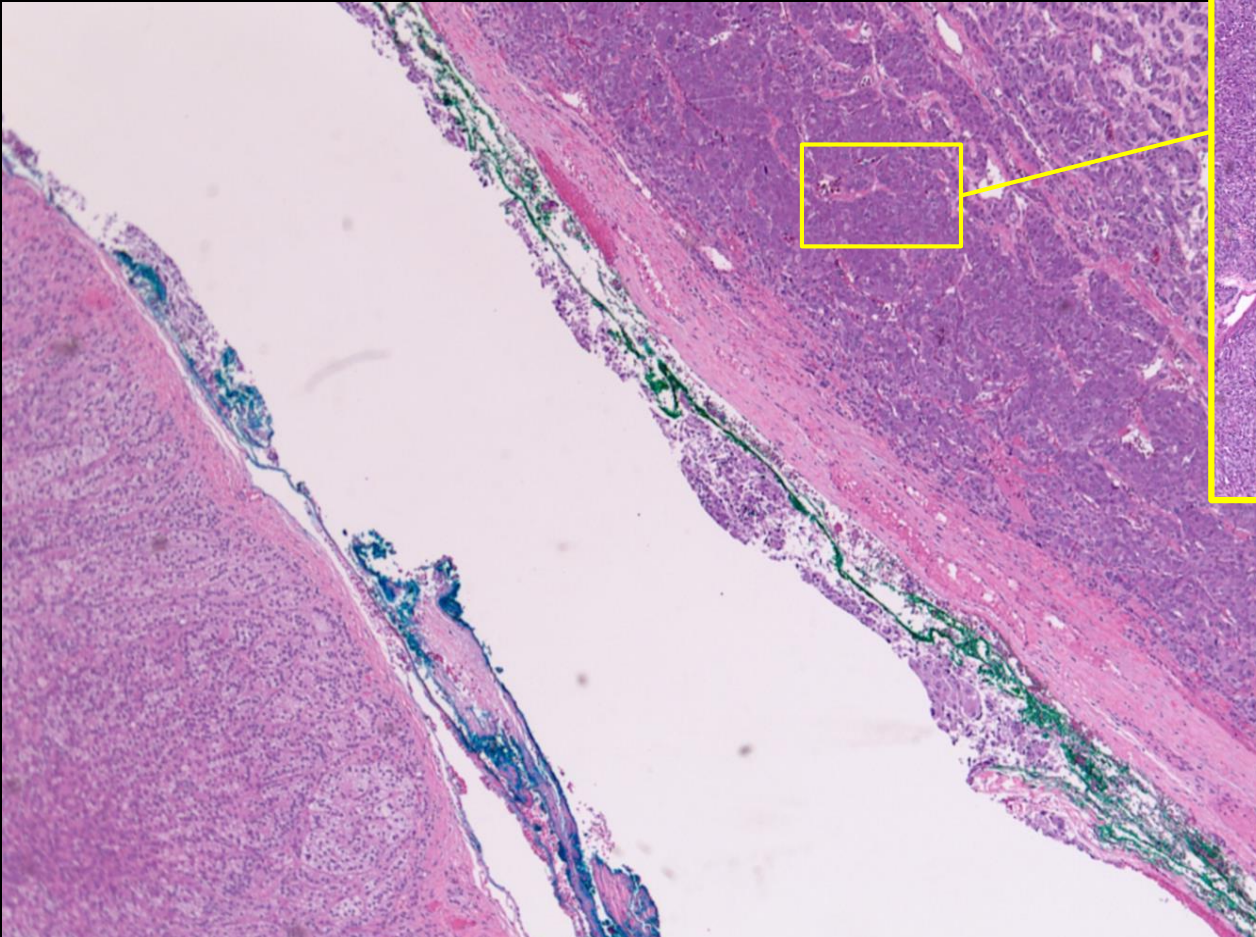


# Histopathological Findings

Tissue from mass  
surrounded by  
fibrous capsule



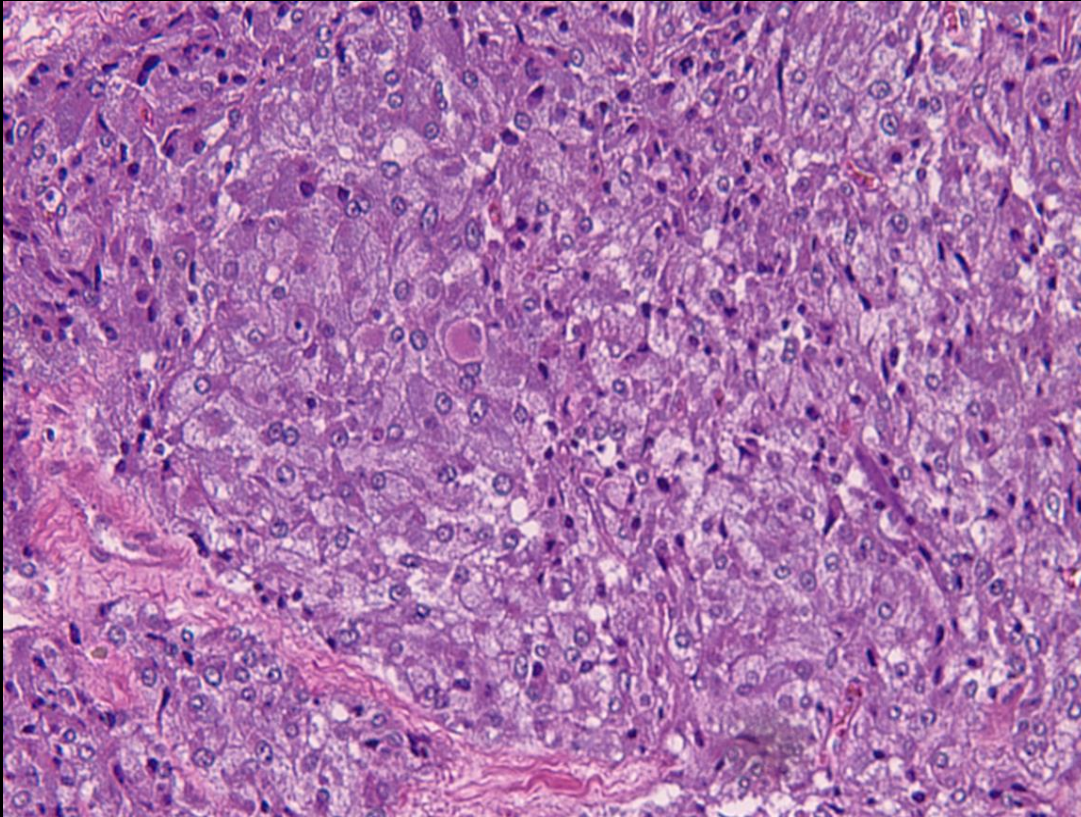
H&E Stain, Low power  
Mass arranged in sheets and  
nests



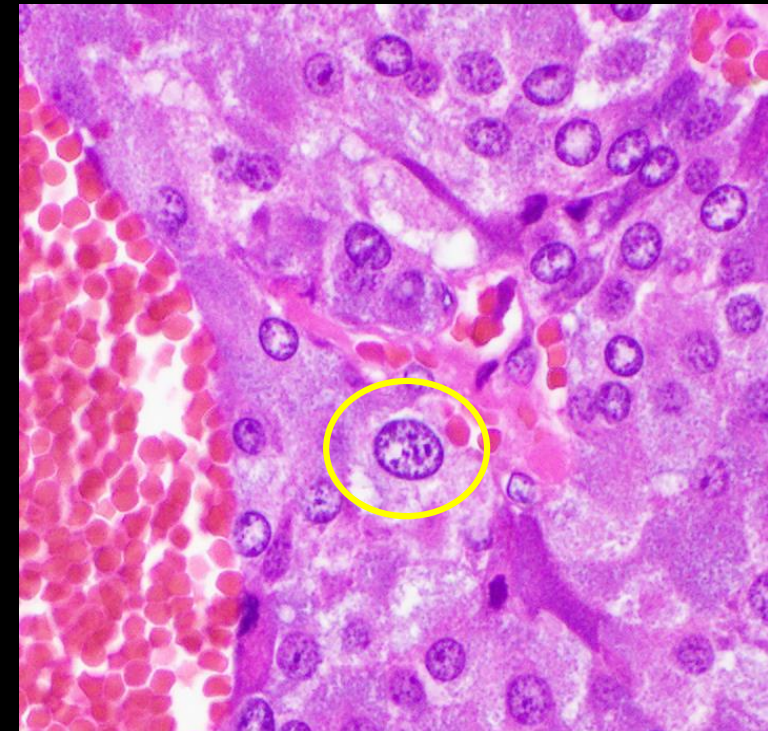Normal-appearing  
adrenal gland  
tissue



# Histopathological Findings of Mass



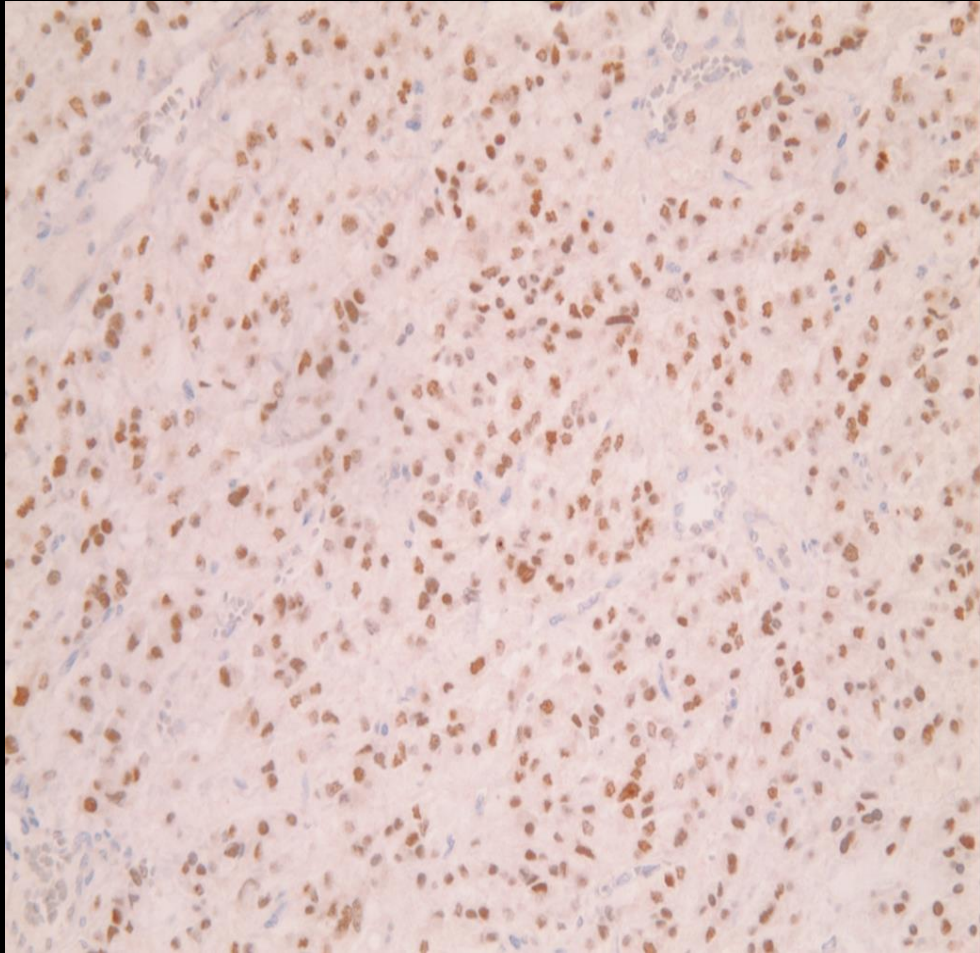
H&E Stain, High power  
Large pleomorphic cells with amphophilic granular  
cytoplasm



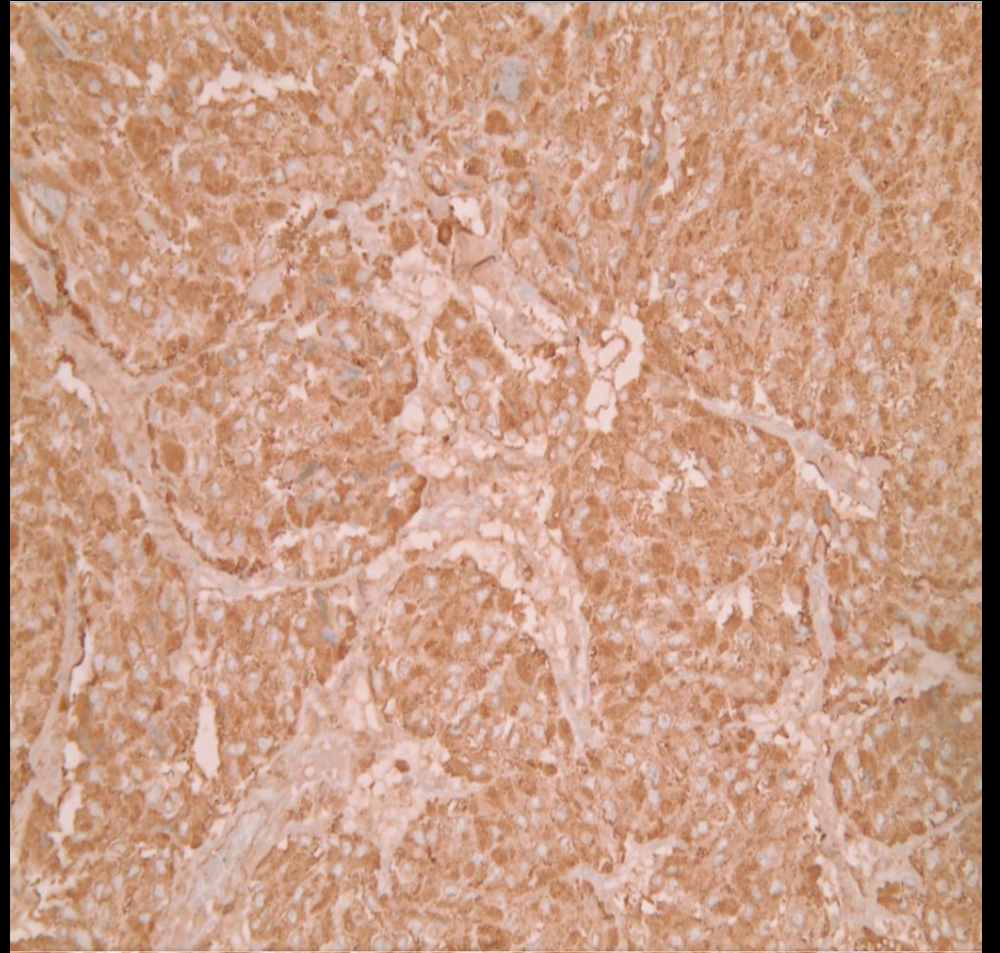
H&E Stain, High power  
Cell nuclei have finely stippled (salt and pepper)  
chromatin



# Histopathological Findings of Mass (stains)



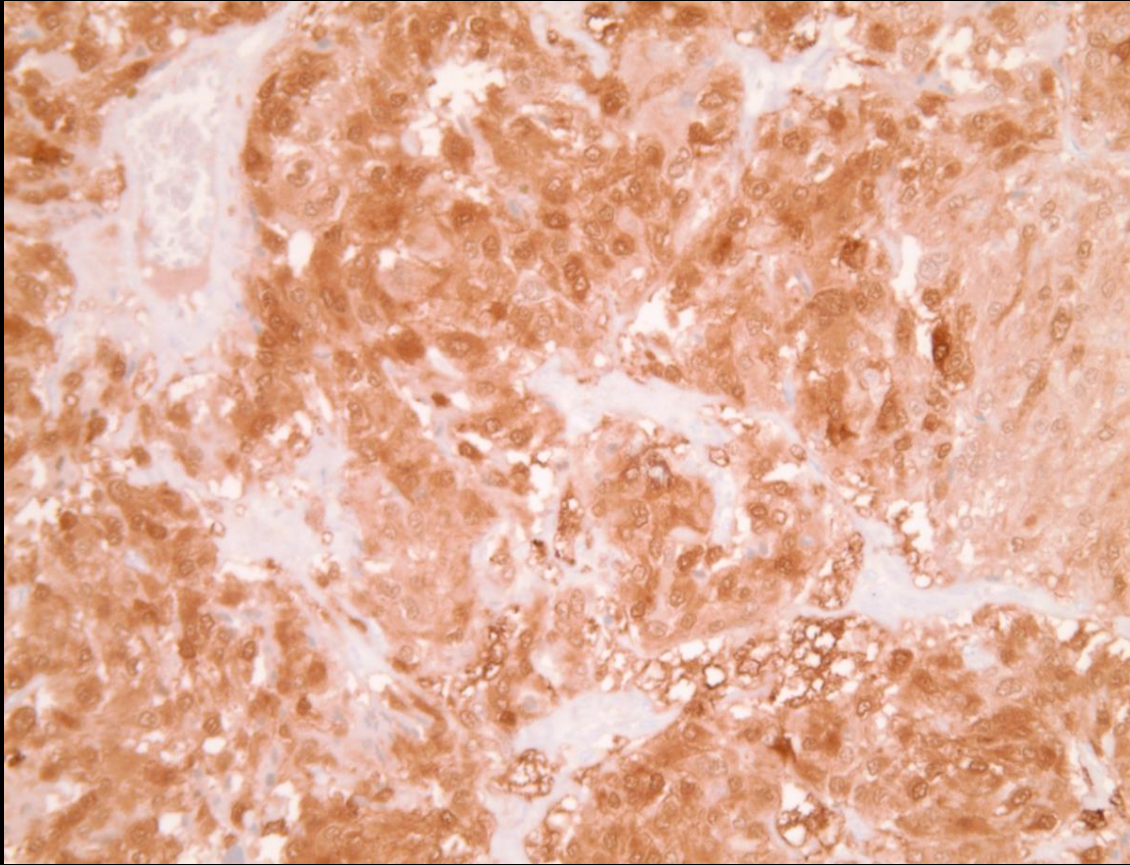
GATA3 +



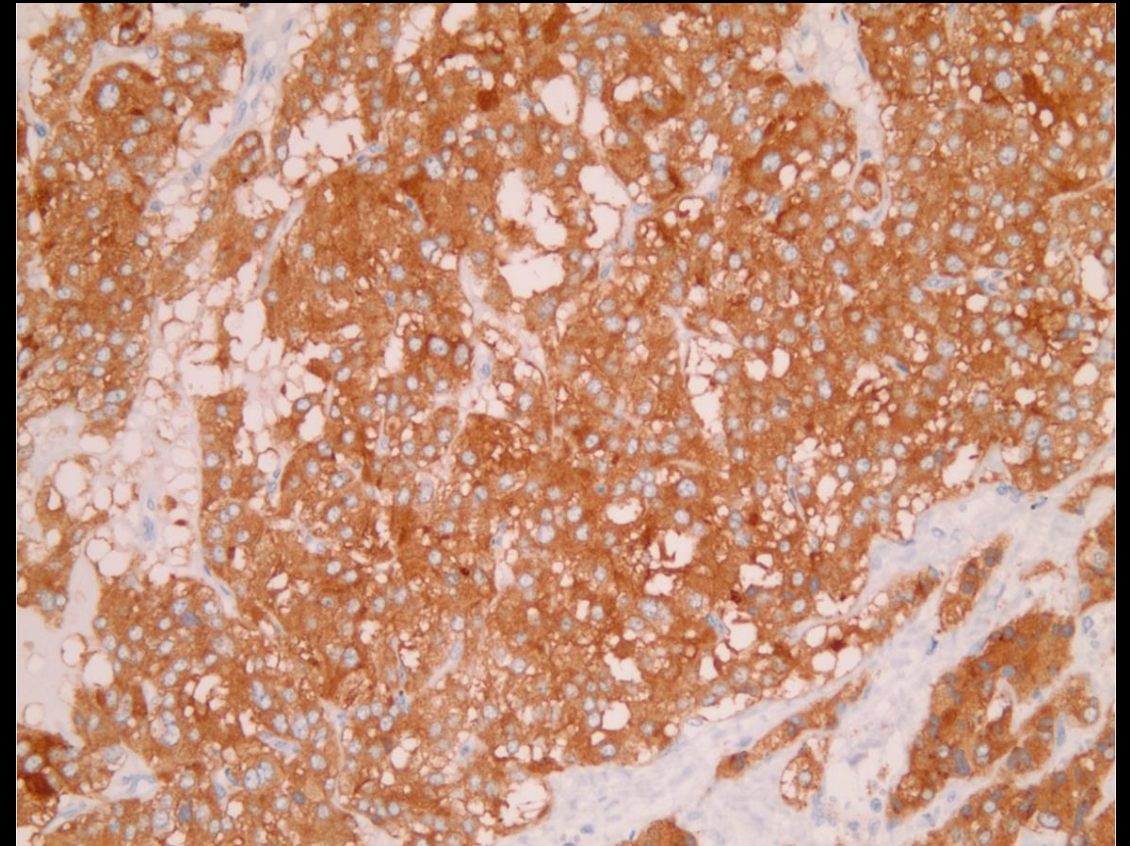
Chromogranin +



# Histopathological Findings of Mass (stains)



S100 +



Synaptophysin +

Final Dx:

Paraganglioma

# Case Discussion: Background

- Paragangliomas are rare neuroendocrine tumors arising from **chromaffin cells** in sympathetic or parasympathetic ganglia in the chest, abdomen, or pelvis, or from the parasympathetic ganglia of the head and neck
- Also known as **extra-adrenal pheochromocytomas**
- Pheochromocytomas and paragangliomas are estimated to occur in about 2-8 of 1 million persons per year

# Case Discussion: Clinical Presentation

- Chromaffin cells secrete catecholamines and cause variable and nonspecific symptoms in patients
- Symptoms can include hypertension, headache, pallor, palpitations, diaphoresis, and anxiety
- Majority of paragangliomas are diagnosed through a workup of an incidentaloma

# Case Discussion: Diagnosis and Treatment

- **Biochemical testing** to look for elevated free plasma metanephrines and normetanephrines and **imaging**, usually a CT scan, to detect the mass.
- Both are crucial to pinpoint a paraganglioma, but the gold standard of diagnosis is **pathology** which classically shows clusters/nests of cells (**zellballen pattern**) separated by fibrovascular stroma that are positive for neuroendocrine markers, such as chromogranin and synaptophysin
- **Treatment:** Surgical excision of mass
  - Important for patients to be on alpha blocker preoperatively to prevent hypertensive crisis during anesthesia

# References:

- Granberg D, Juhlin CC, Falhammar H. Metastatic Pheochromocytomas and Abdominal Paragangliomas. *J Clin Endocrinol Metab.* 2021;106(5):e1937-e1952. doi:[10.1210/clinem/dgaa982](https://doi.org/10.1210/clinem/dgaa982)
- Lee KY, Oh YW, Noh HJ, et al. Extraadrenal Paragangliomas of the Body: Imaging Features. *American Journal of Roentgenology.* 2006;187(2):492-504. doi:[10.2214/AJR.05.0370](https://doi.org/10.2214/AJR.05.0370)
- Lenders JWM, Duh QY, Eisenhofer G, et al. Pheochromocytoma and Paraganglioma: An Endocrine Society Clinical Practice Guideline. *The Journal of Clinical Endocrinology & Metabolism.* 2014;99(6):1915-1942. doi:[10.1210/jc.2014-1498](https://doi.org/10.1210/jc.2014-1498)
- Pacak K, Tella SH. Pheochromocytoma and Paraganglioma. In: Feingold KR, Anawalt B, Boyce A, et al., eds. *Endotext.* MDText.com, Inc.; 2000. Accessed June 22, 2022. <http://www.ncbi.nlm.nih.gov/books/NBK481899/>