

AMSER Case of the Month:

Breast Implant-Associated Anaplastic Large Cell Lymphoma (BIA-ALCL)

John Nestler, MS4

Virginia Commonwealth University SOM

Dr. Peter Haar

Department of Radiology

Dr. Alden Chesney

Department of Pathology

Patient Presentation

- 45-year-old previously healthy female with past medical history of bilateral breast augmentation 15 years prior presents with a subacute onset of right breast pain and focal swelling.
- She reports tightening of breast tissue five years prior, but last mammography three years ago showed no concerning findings.
- She is otherwise healthy and has had no other surgeries.
- Family history notable for breast and prostate cancer.
- Physical exam reveals right breast skins changes, pain, swelling, and a palpable inferomedial mass.

What Imaging Should We Order?

Select the applicable ACR Appropriateness Criteria

Revised 2016

American College of Radiology ACR Appropriateness Criteria® Palpable Breast Masses

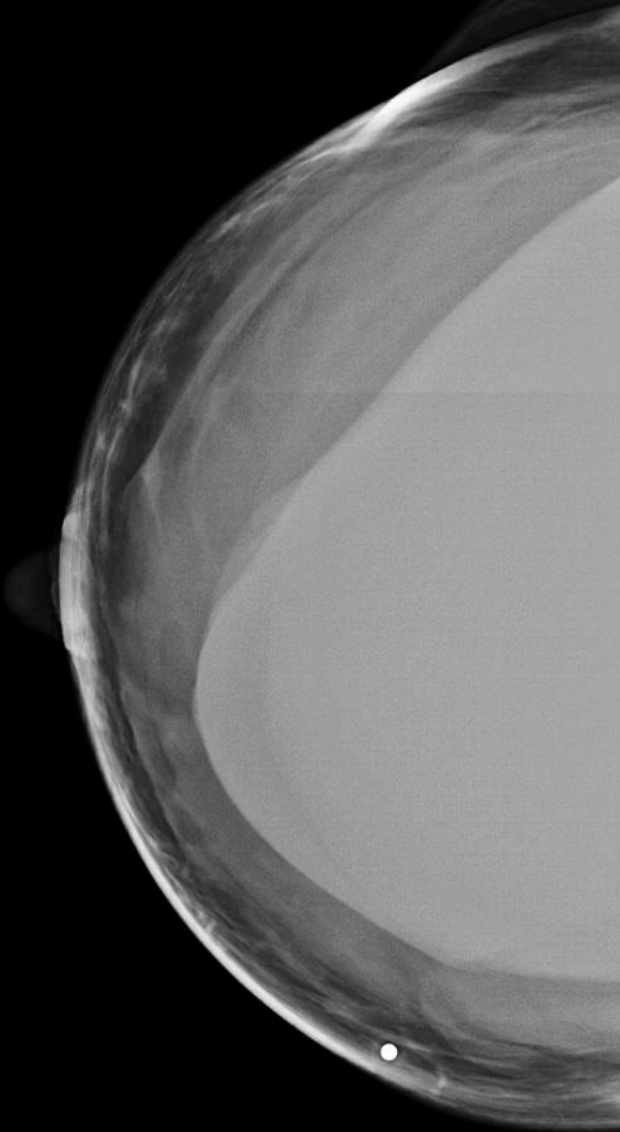
Variant 1: Palpable breast mass. Female, 40 years of age or older, initial evaluation. (See [Appendices 1A-1B](#) for additional steps in the workup of these patients.)

Radiologic Procedure	Rating	Comments	RRL*
Mammography diagnostic	9	See references [13-15].	☼☼
Digital breast tomosynthesis diagnostic	9	See references [16-18,20,85].	☼☼
US breast	4	If she had recent mammogram (ie, past 6 months), US may be appropriate.	○
MRI breast without and with IV contrast	2	See references [4,49].	○
MRI breast without IV contrast	1		○
FDG-PEM	1		☼☼☼☼
Sestamibi MBI	1		☼☼☼
Image-guided core biopsy breast	1		Varies
Image-guided fine-needle aspiration breast	1		Varies
Rating Scale: 1,2,3 Usually not appropriate; 4,5,6 May be appropriate; 7,8,9 Usually appropriate			*Relative Radiation Level

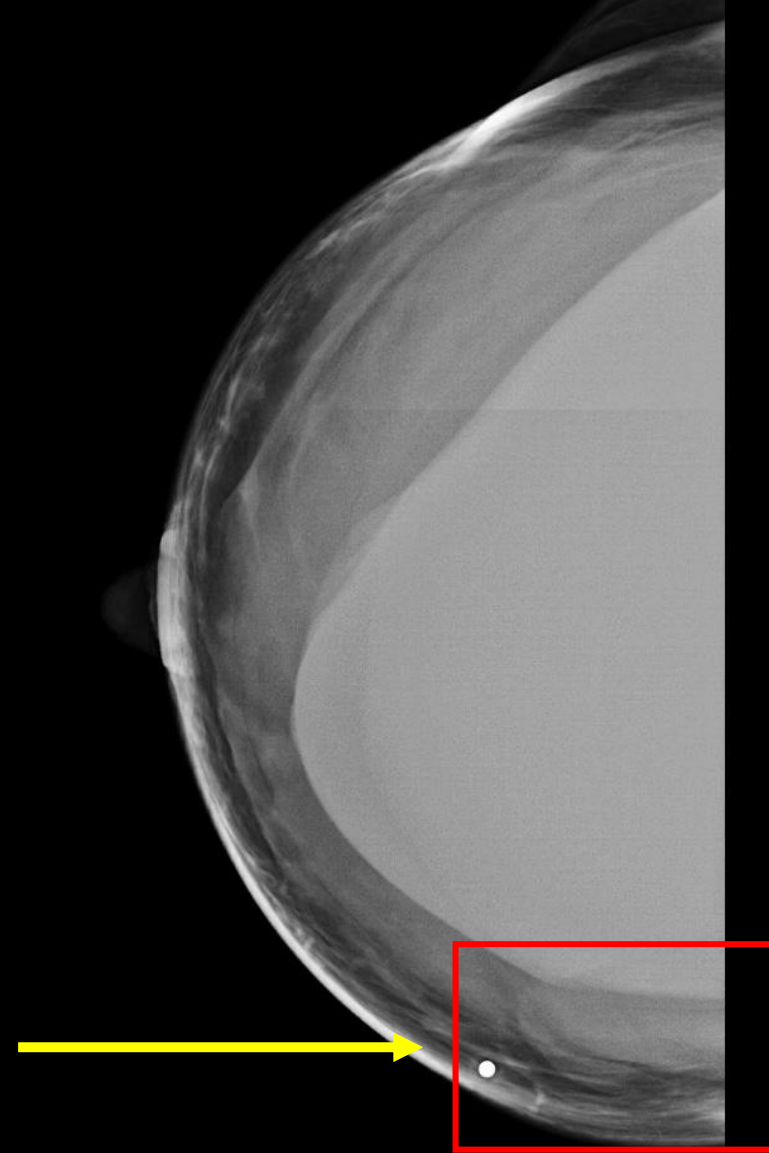
This imaging modality was ordered by the physician



Right Breast Mammography

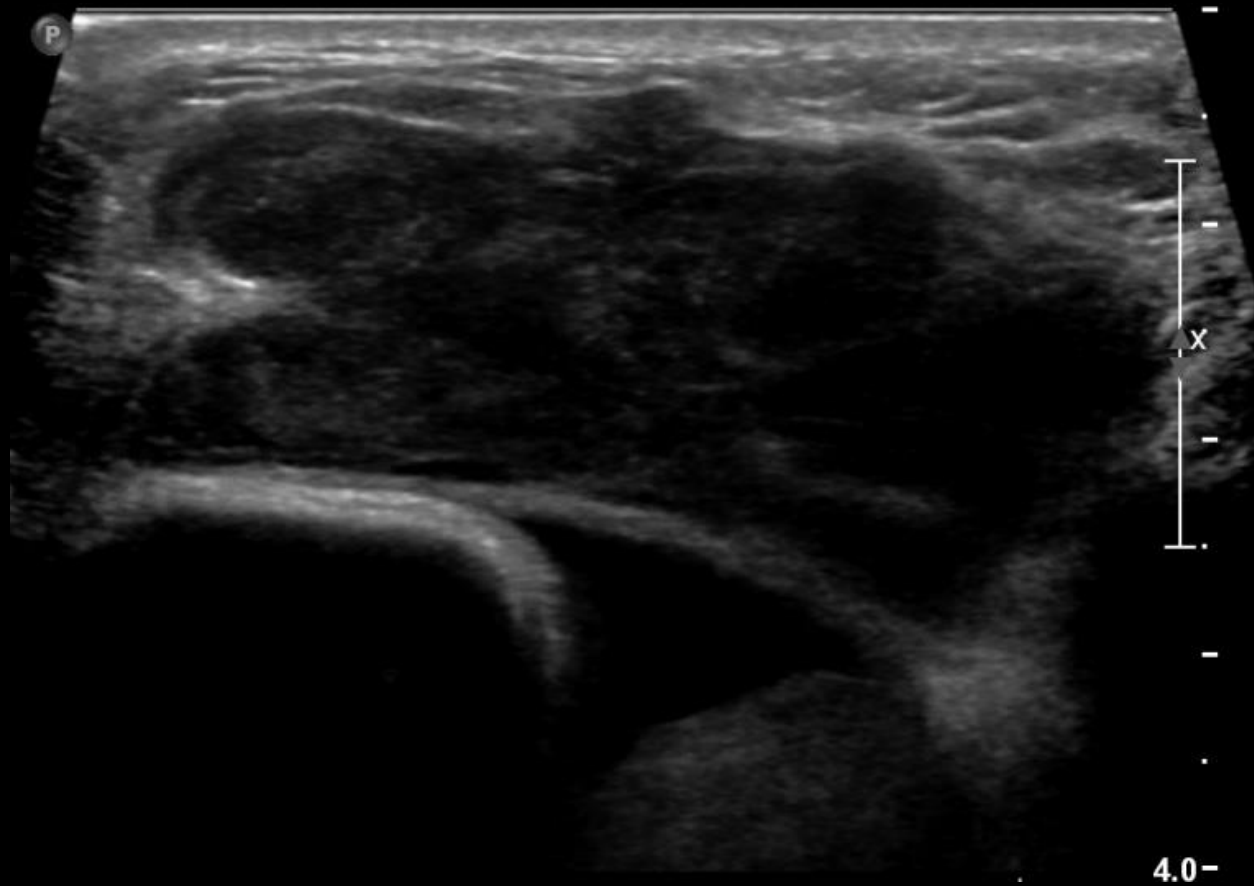


Right Breast Mammography



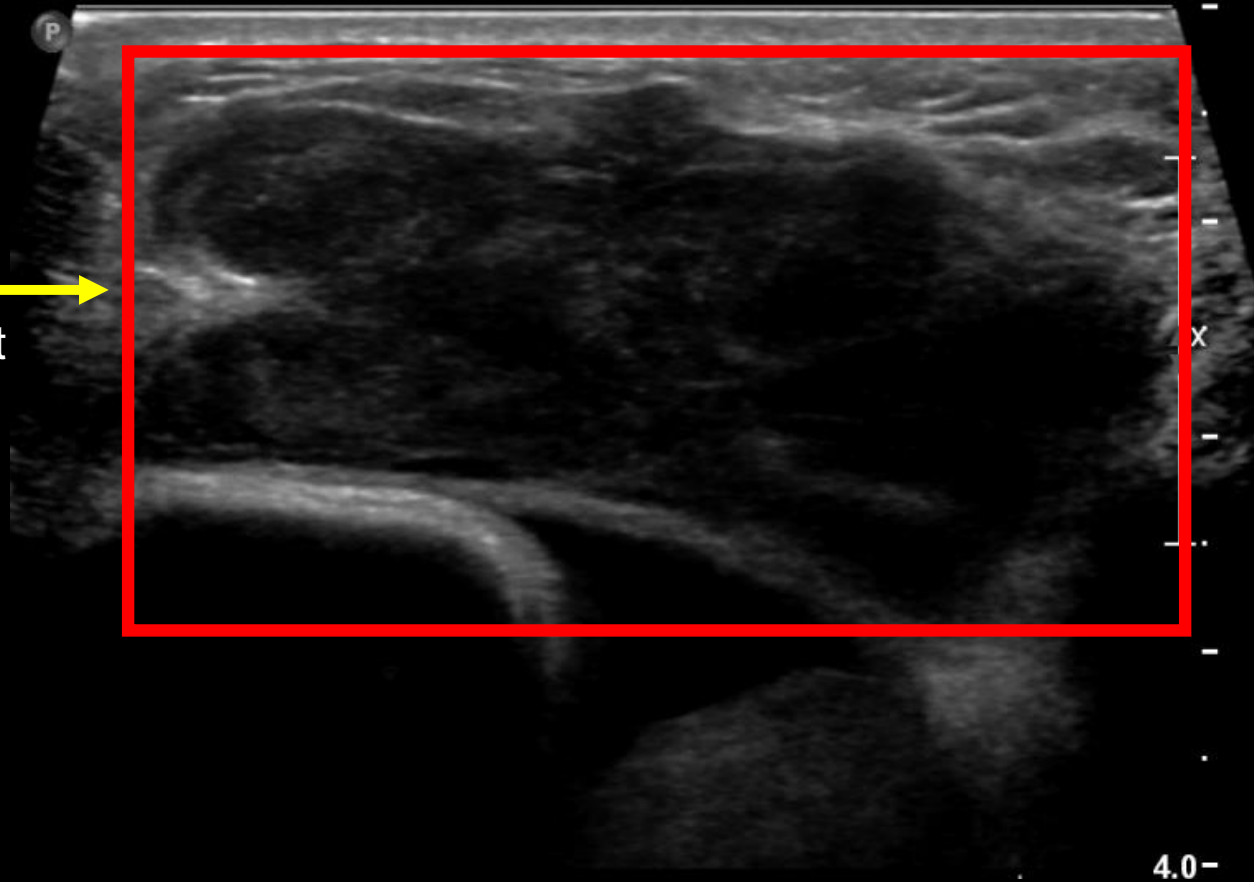
Circumferential density surrounding implant and mass effect in inferomedial quadrant of right breast.

Right Breast Ultrasound



Right Breast Ultrasound

Approximately 5x2x3 cm
heterogenous mass with
circumscribed and indistinct
margins.



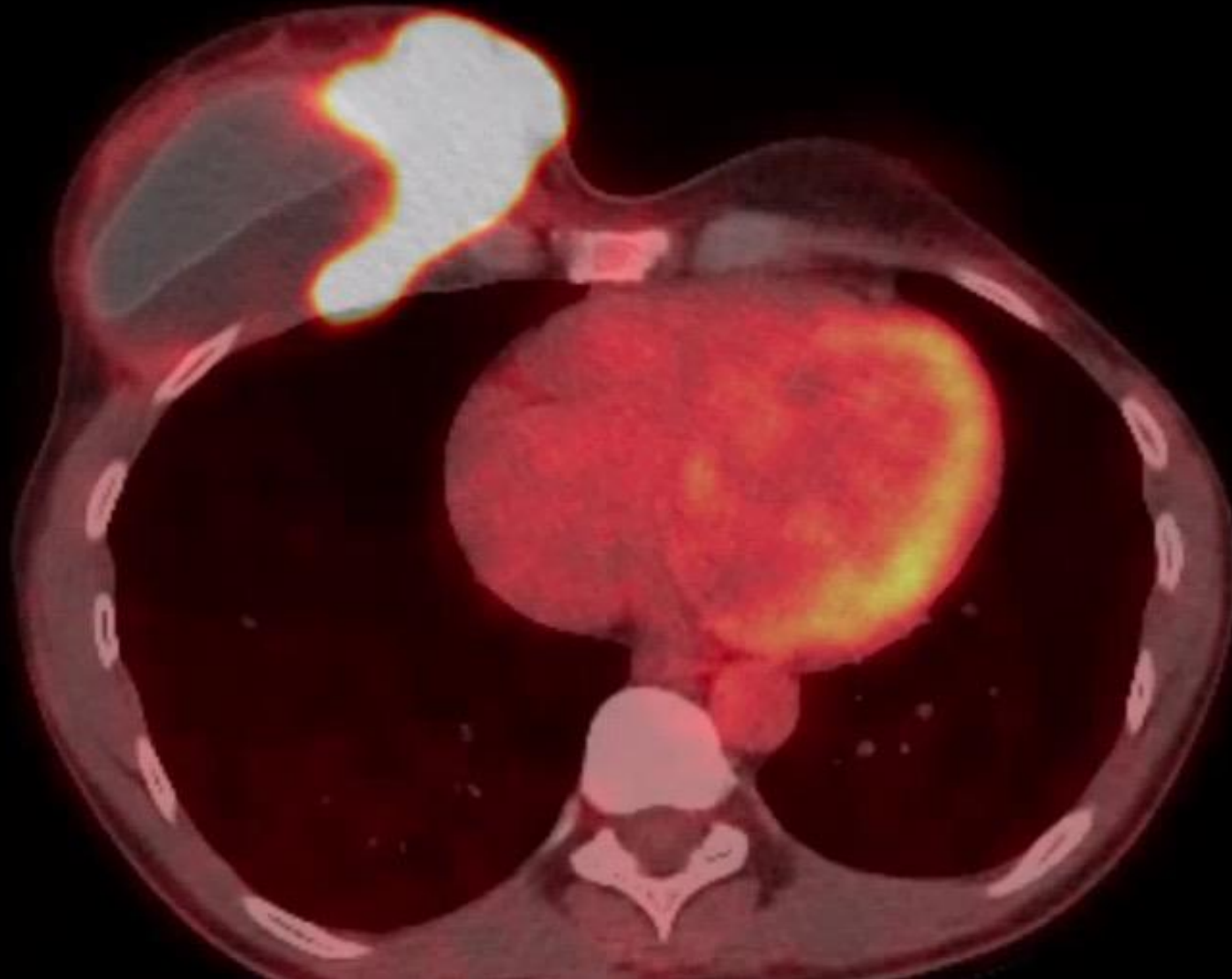
Differential Diagnosis of Breast Masses

- Fibrocystic disease
- Breast cancer
- Breast cyst
- Breast adenosis
- Breast abscess
- Fat necrosis
- Fibroadenoma

Further Workup

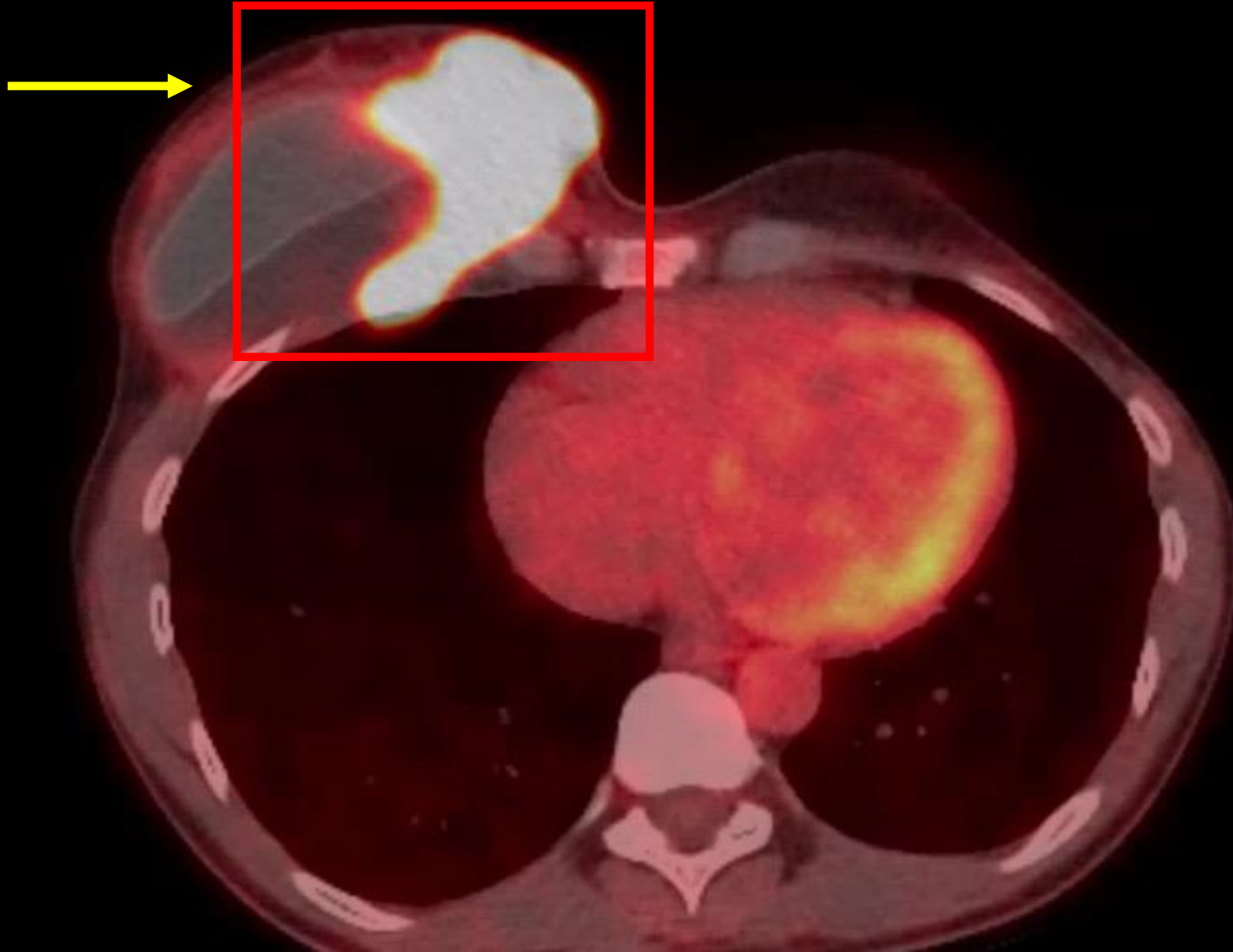
- Following mammography patient had a breast biopsy and seroma aspiration.
- Analysis revealed abnormal pleomorphic cells staining positive for CD30+, CD45 focal weak+, and CD2+.
- PET/CT imaging was ordered to fully characterize the mass.

PET/CT

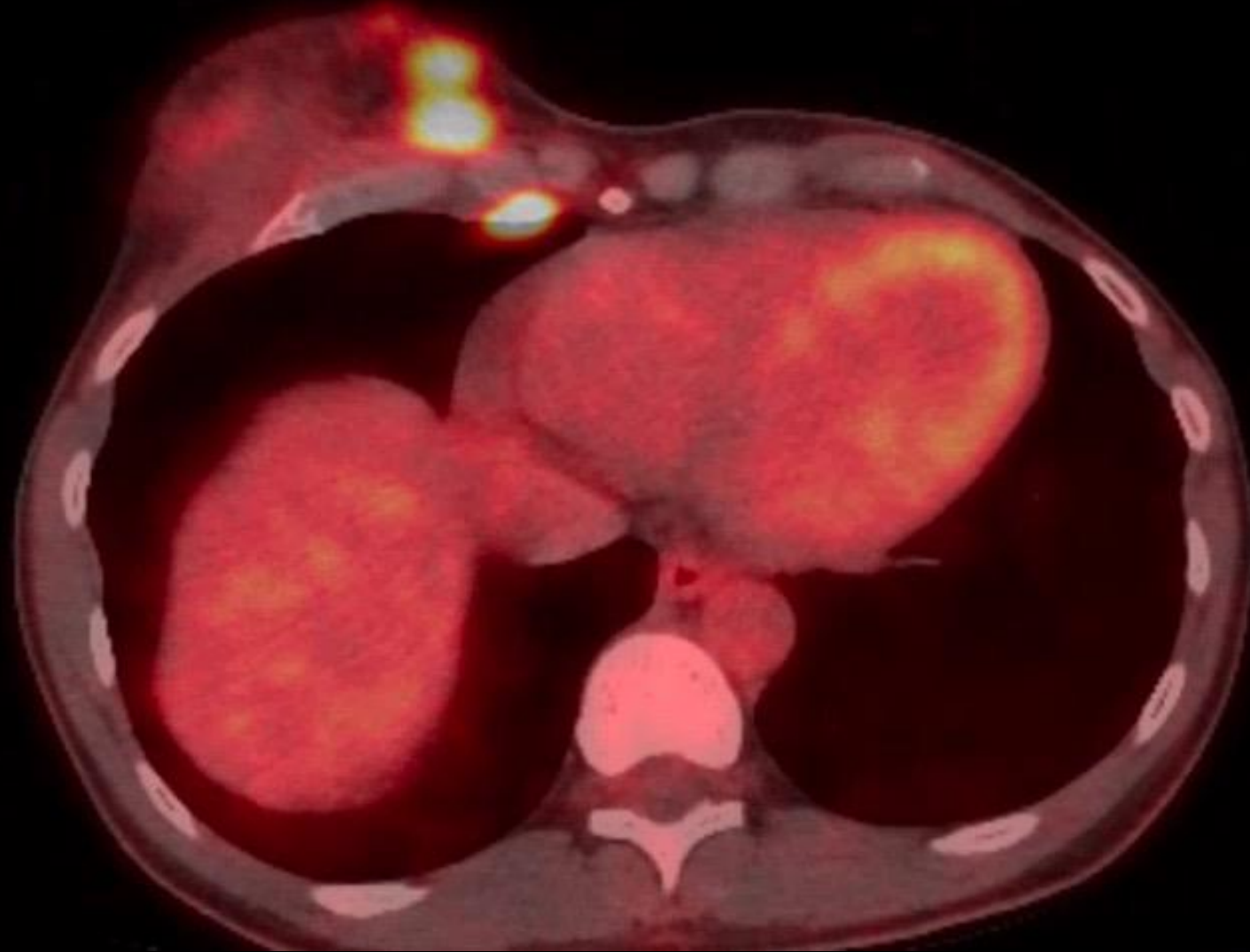

PET/CT

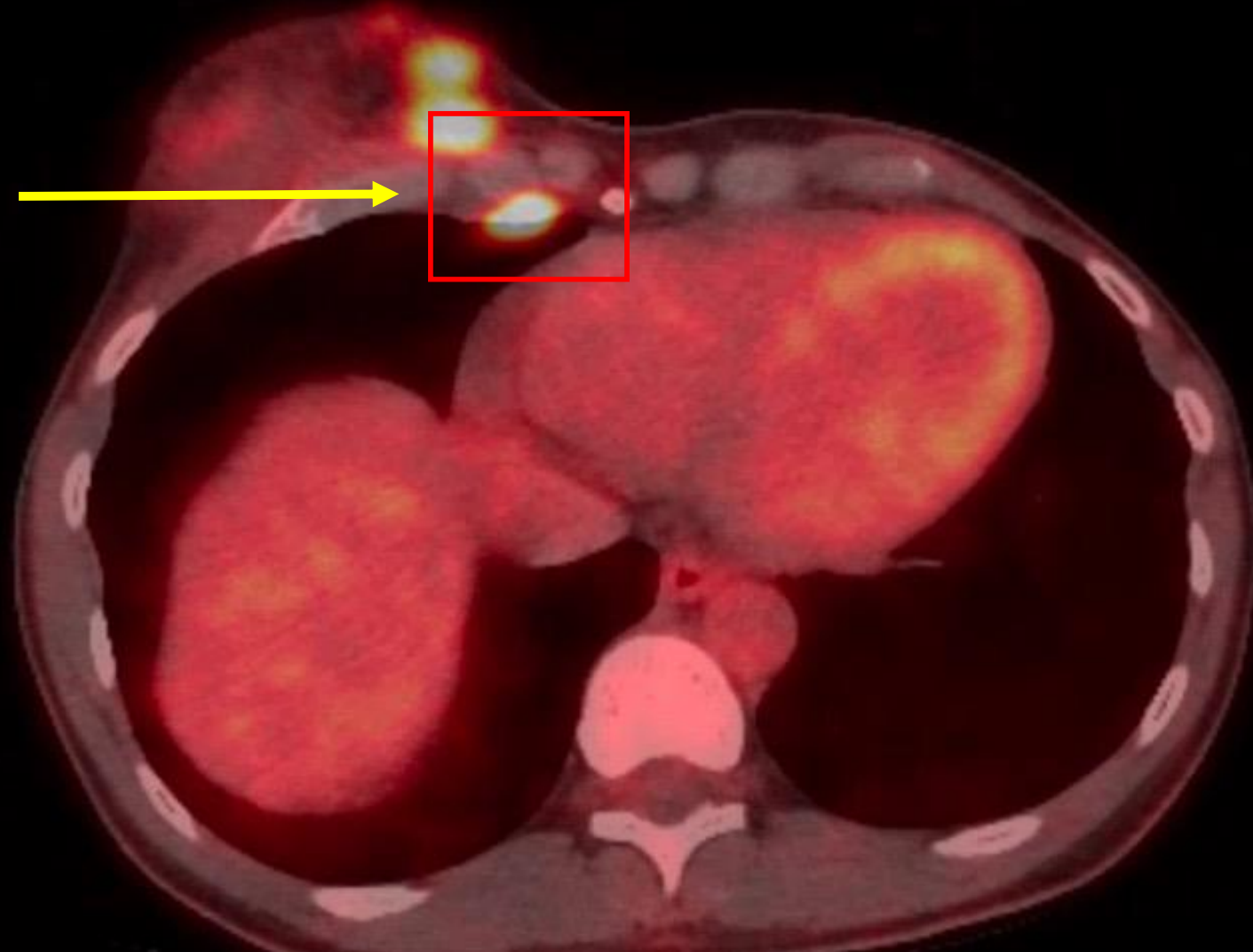
Avid FDG uptake throughout inner quadrant of right breast with extension to the level of the chest wall. SUV max 28.6.



PET/CT



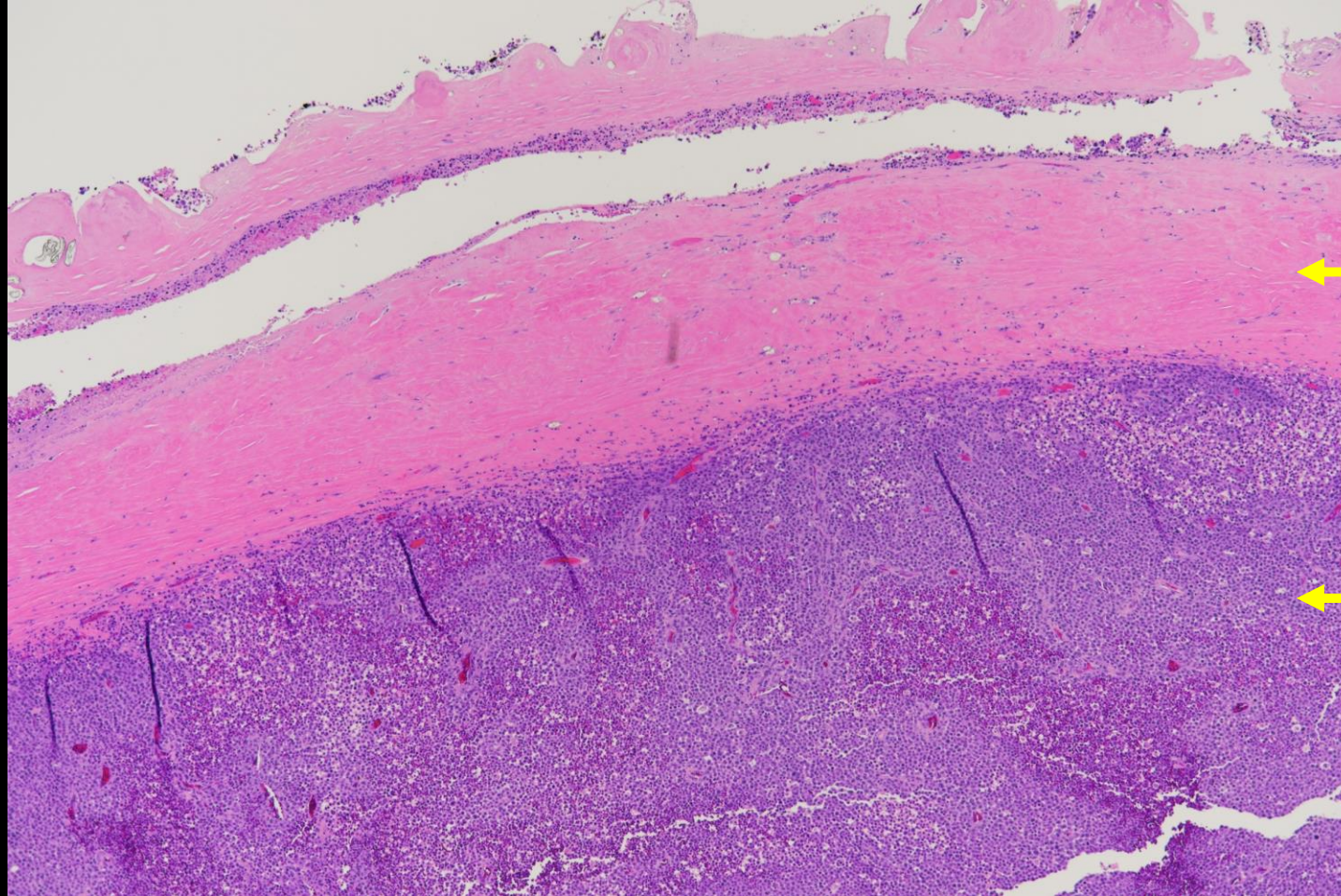
PET/CT



Uptake in internal mammary node deep to right breast. SUV max of 8.8.

Micro Path

Breast mass with neoplastic cells shown traversing necrotic tissue of the adjacent breast capsule.

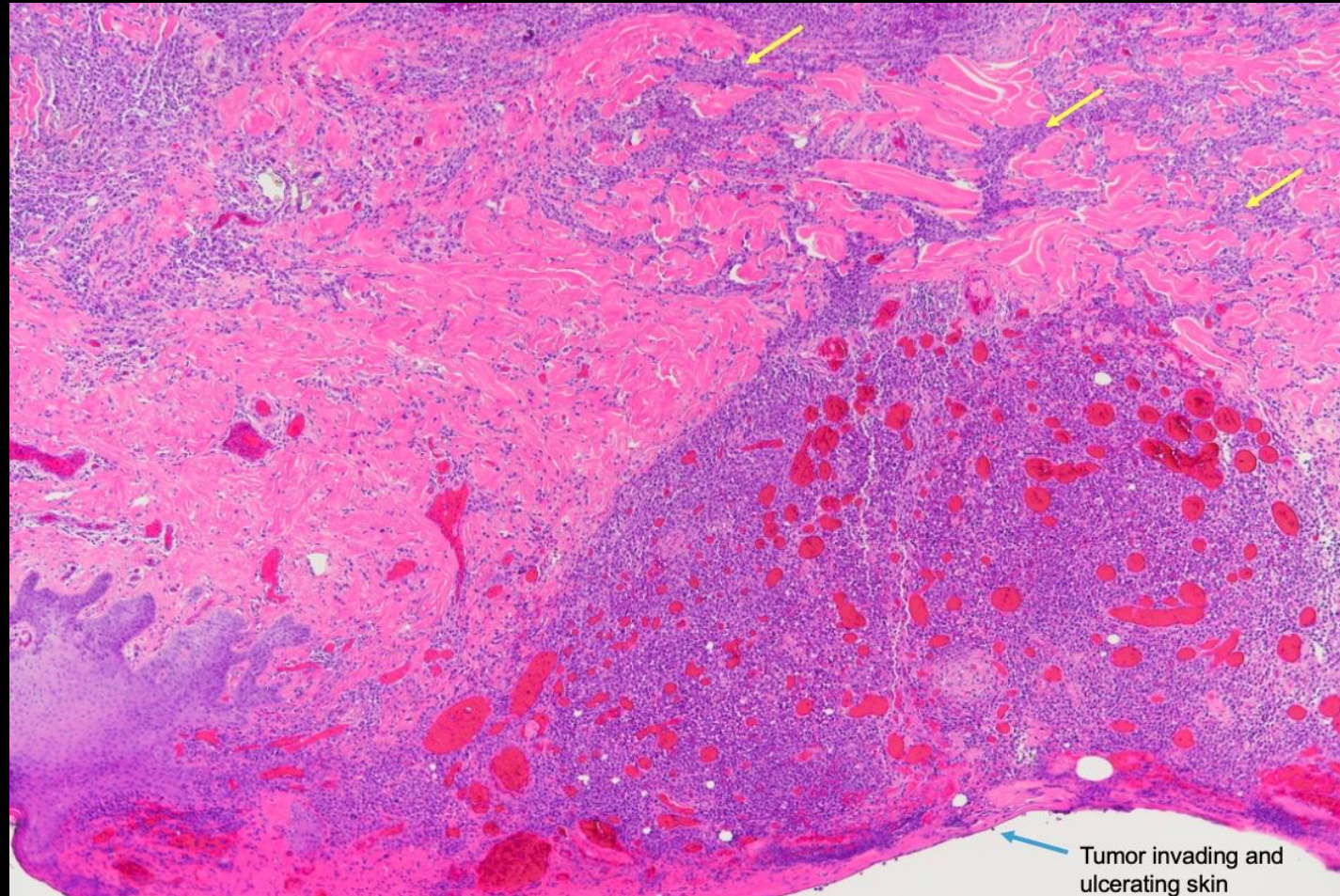


← Implant capsule

← Breast mass

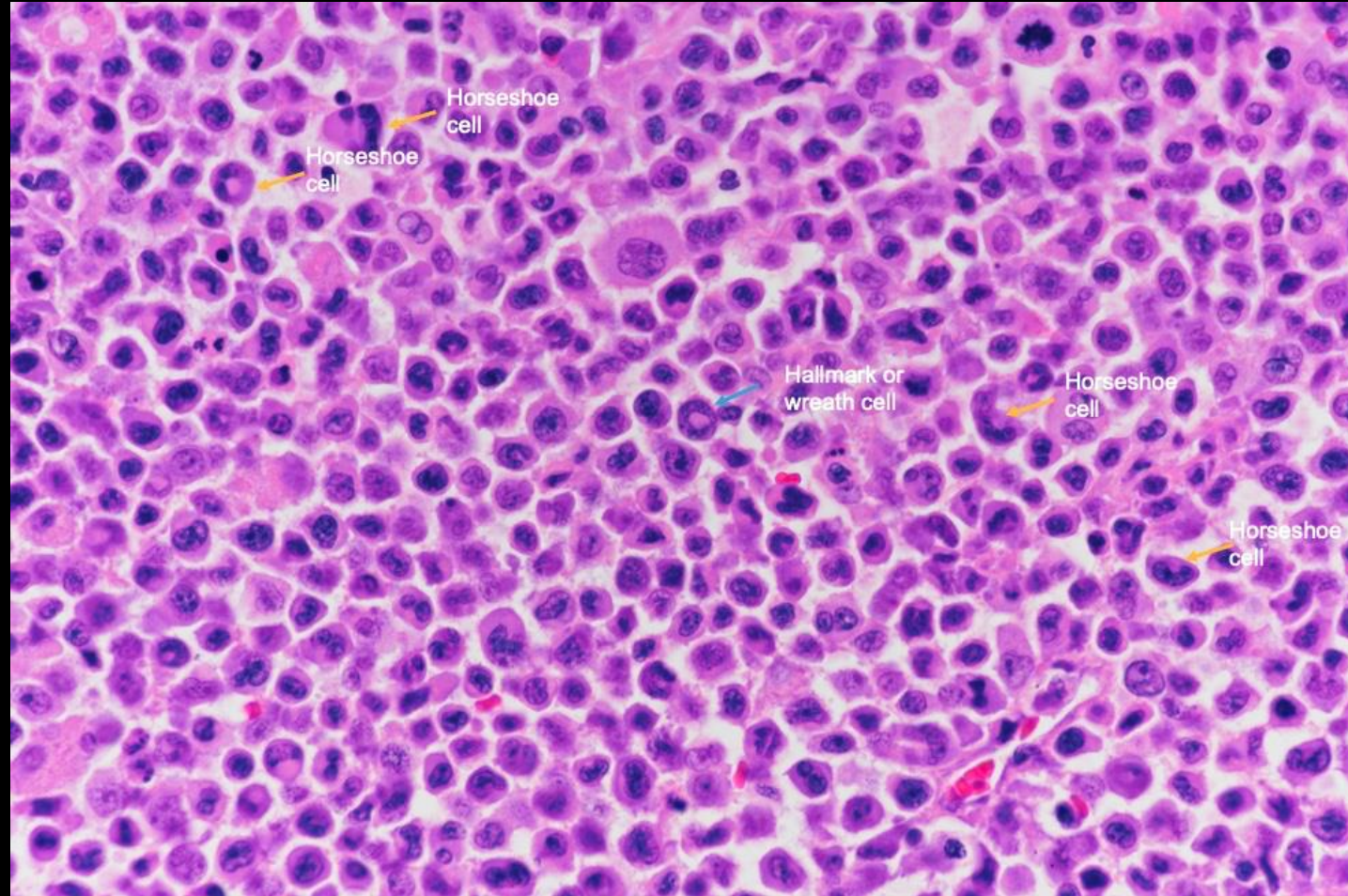
Micro Path

Infiltration of tumor mass (yellow arrows) through dermis with invasion and ulceration of overlying skin.



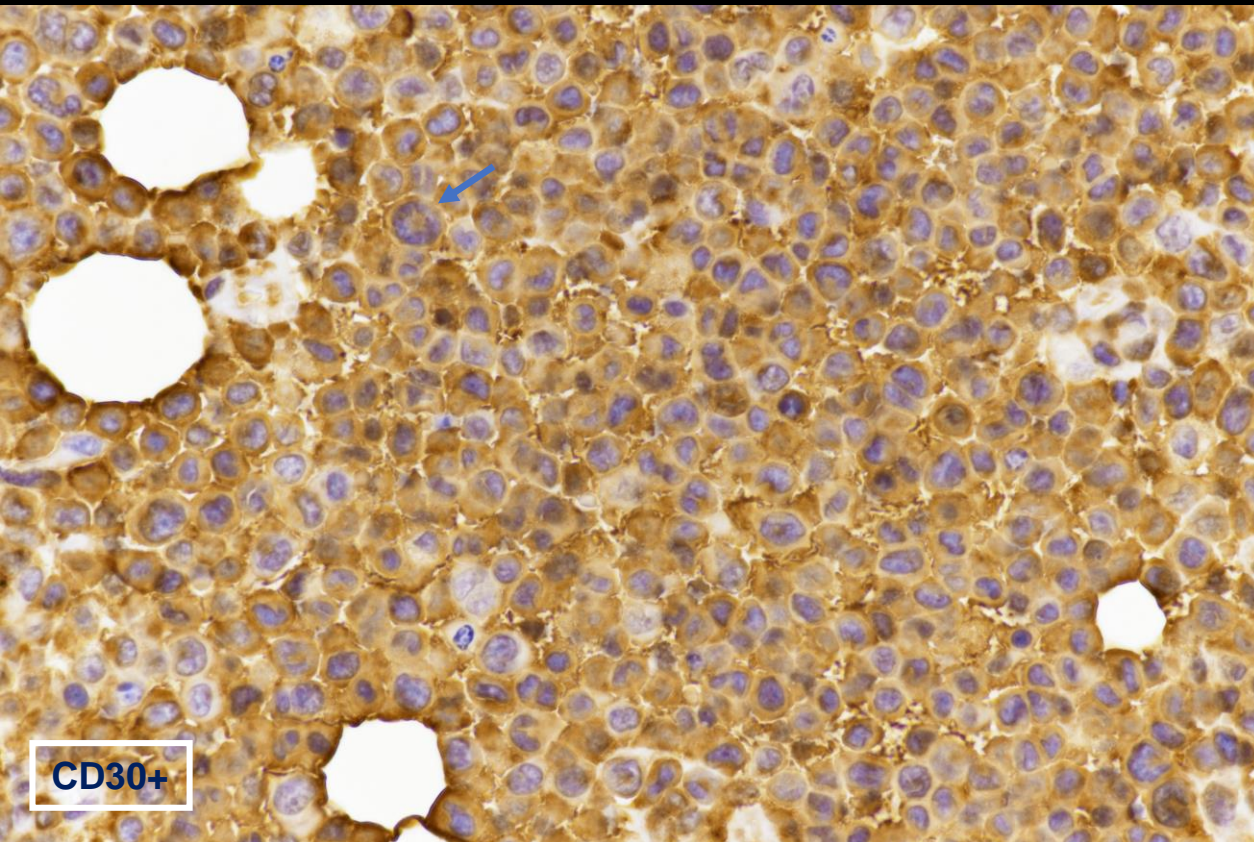
Micro Path

Characteristic features of ALCL including horseshoe cells (yellow) and hallmark cells (blue).



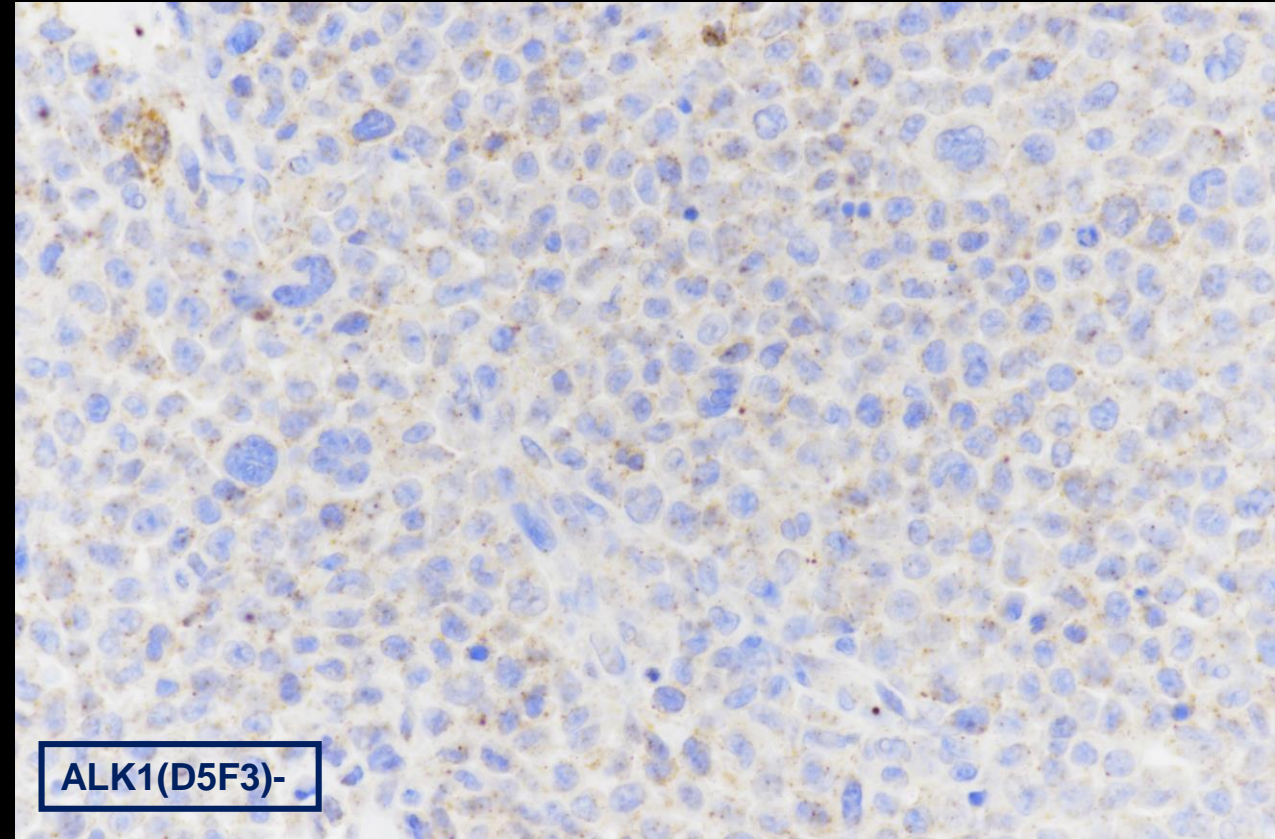
Immunostaining

CD30



Neoplastic cells are strongly diffusely CD30 positive, including Hallmark cell (arrow)

ALK-1



Neoplastic cells are ALK-1 negative, including Hallmark cells and horseshoe cells

Final Dx:

Breast Implant-Associated Anaplastic Large Lymphoma
(BIA-ALCL)

Case Discussion

- BIA-ALCL is a rare peripheral T cell non-Hodgkin lymphoma first reported in 1997. It is characterized by pleomorphic CD30+, ALK negative lymphoid cells.
- This disease is associated with textured breast implants, and the pathogenesis may stem from inflammation caused by microtrauma or biofilm formation due to the textured surface.
- On average symptoms usually develop 8-10 years following augmentation.
- Presentation usually consists of a peri-implant effusion, but more advanced disease states can also be associated with a mass.

Case Discussion

- Prompt identification of BIA-ALCL is crucial to treatment, and initial workup should consist of ultrasound or MRI, breast biopsy, and seroma aspiration with flow cytometry.
- PET/CT should be utilized for staging prior to surgical management.
- Complete capsulectomy and implant removal with negative margins is the current standard of care. More advanced disease states may require adjuvant chemotherapy and radiation therapy.
- This disease has a favorable prognosis if detected at the seroma stage, while higher mortality rates are seen in patients with a mass.

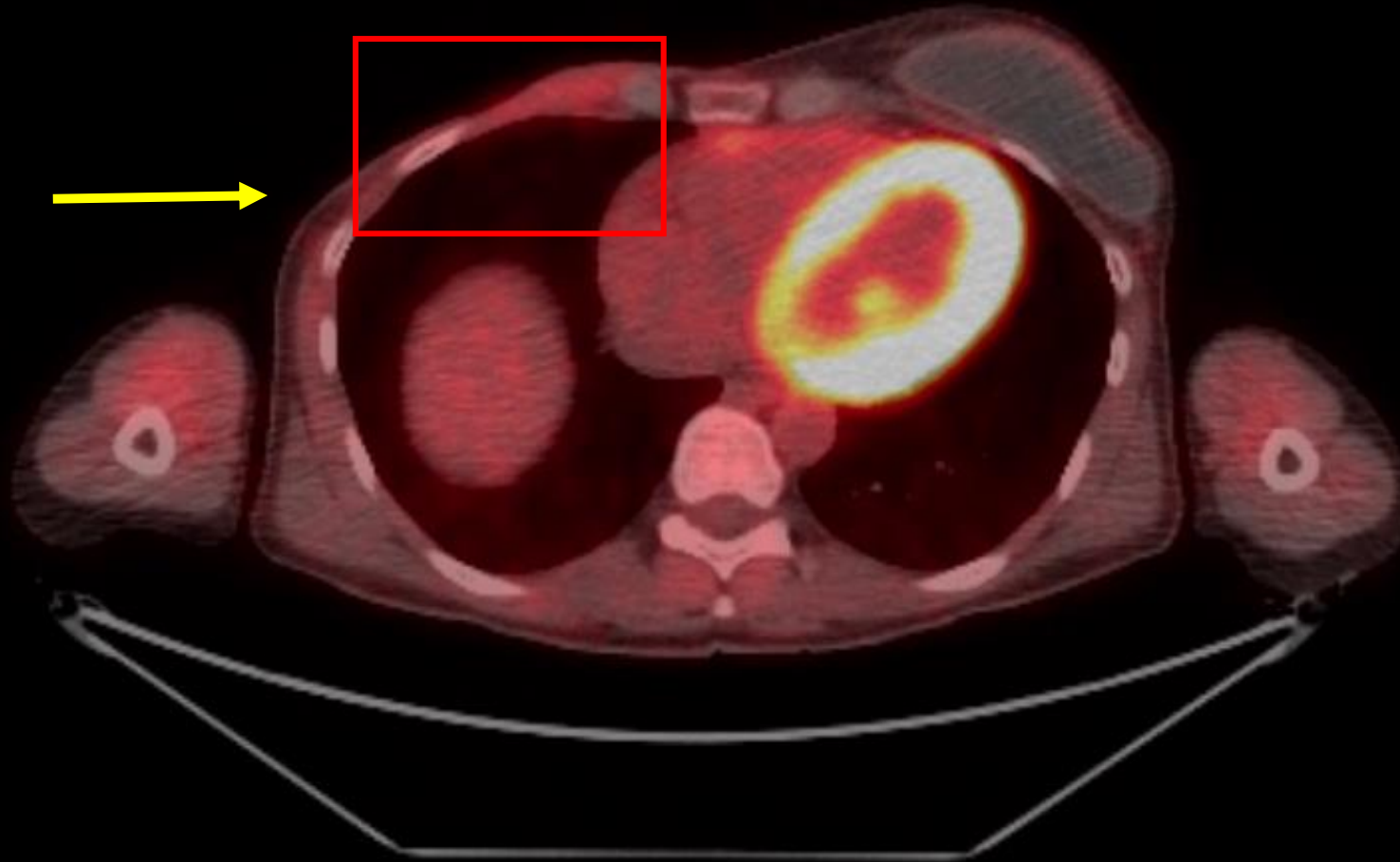Back to Our Patient

- Patient underwent right total mastectomy with incomplete (R2) resection of tumor due to chest wall invasion.
- Left implant resected en-block and replaced with smooth silicone implant.
- Postoperative course complicated by pathologic rib fracture and hematoma from residual tumor.
- Patient underwent 5 cycles of adjuvant chemotherapy followed by consolidative radiation therapy.
- No signs of recurrent or residual disease on follow up PET.

PET/CT: 8 months after mastectomy

Resolving postsurgical changes with max SUV 1.8.

No signs of recurrent or persistent disease.



References:

- Brody GS, Deapen D, Taylor CR, et al. Anaplastic large cell lymphoma occurring in women with breast implants: Analysis of 173 cases. *Plast Reconstr Surg*. 2015;135(3):695-705. doi:10.1097/PRS.0000000000001033
- Clemens MW, Jacobsen ED, Horwitz SM. 2019 NCCN Consensus Guidelines on the Diagnosis and Treatment of Breast Implant-Associated Anaplastic Large Cell Lymphoma (BIA-ALCL). *Aesthetic Surg J*. 2019;39(Suppl_1):S3-S13. doi:10.1093/asj/sjy331
- Daly C, Puckett Y. Approach New Breast Mass. *StatPearls*. April 2021. <https://www.ncbi.nlm.nih.gov/books/NBK560757/>. Accessed August 1, 2021.
- Doren EL, Miranda RN, Selber JC, et al. U.S. epidemiology of breast implant-associated anaplastic large cell lymphoma. *Plast Reconstr Surg*. 2017;139(5):1042-1050. doi:10.1097/PRS.00000000000003282
- CA G, Z P, S M, K van B, B K. Breast implant-associated anaplastic large cell lymphoma: a systematic review. *Plast Reconstr Surg*. 2015;135(3):713-720. doi:10.1097/PRS.0000000000001037
- M M, H H, D C, A D, K V. The A, B and C's of Silicone Breast Implants: Anaplastic Large Cell Lymphoma, Biofilm and Capsular Contracture. *Mater (Basel, Switzerland)*. 2018;11(12). doi:10.3390/MA11122393
- Moy L, Heller SL, Bailey L, et al. ACR Appropriateness Criteria® Palpable Breast Masses. *J Am Coll Radiol*. 2017;14(5):S203-S224. doi:10.1016/J.JACR.2017.02.033