

# AMSER Case of the Month:

## Paratesticular Rhabdomyosarcoma

Alexis Violette, MS4

Medical University of South Carolina

Dr. Jeanne Hill, M.D. and Dr. Laura Spruill, M.D., Ph.D.

Medical University of South Carolina

# Patient Presentation

- HPI:
  - 14 y.o. male presenting with an enlarging, firm right paratesticular mass initially discovered 3 months prior, but it had been growing more rapidly over the past 2 weeks.
  - He denies trauma to the area, pain, erythema, dysuria, or swelling.
  - PMHx is significant for a left epididymal cyst and ADHD.
- Physical exam:
  - Firm, painless mass in right hemiscrotum measuring approximately 3.0 cm.
  - It does not transilluminate or change in size with supine position or Valsalva.

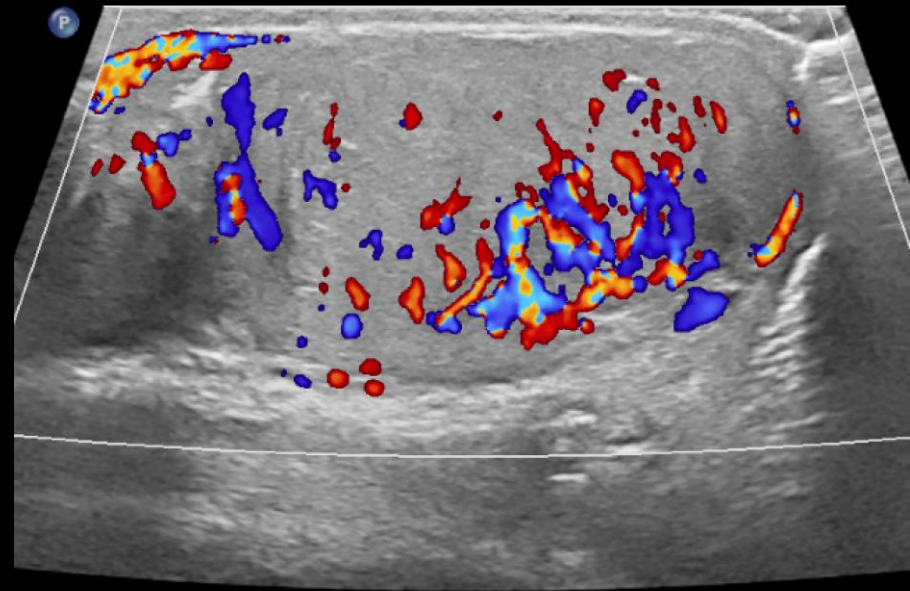
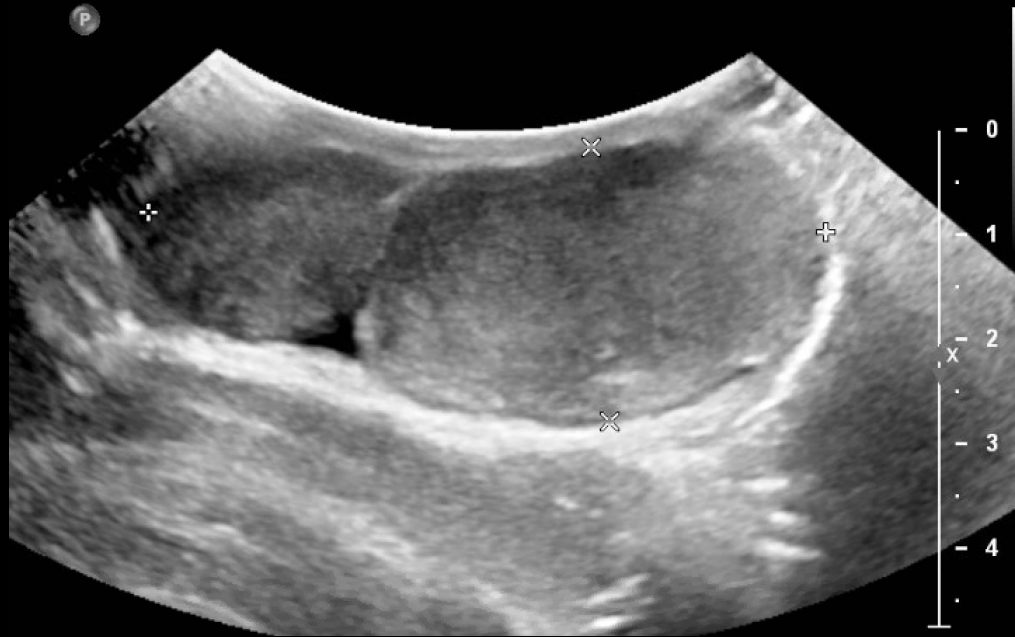# Pertinent Labs

- AFP, LDH, and HCG are within normal limits
- CBC and CMP are within normal limits

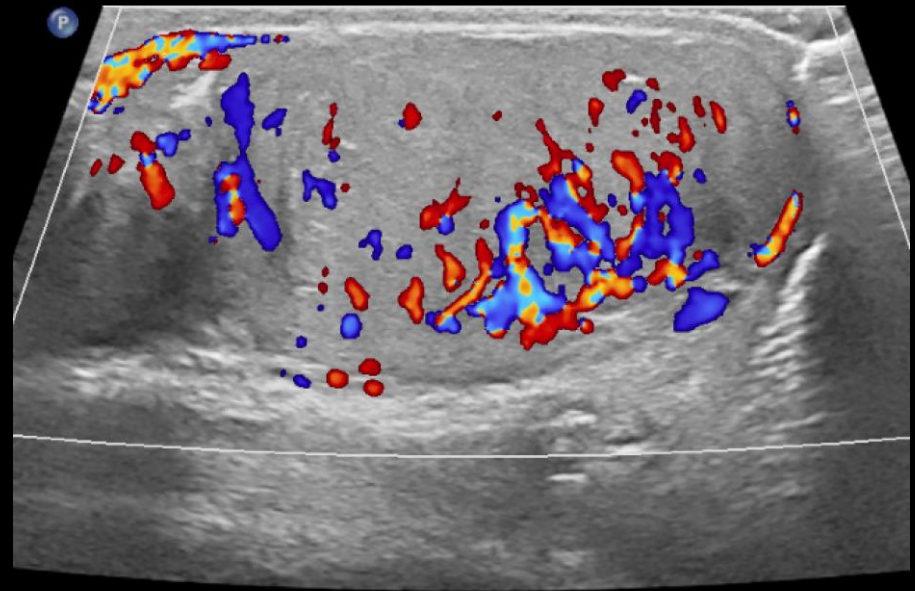
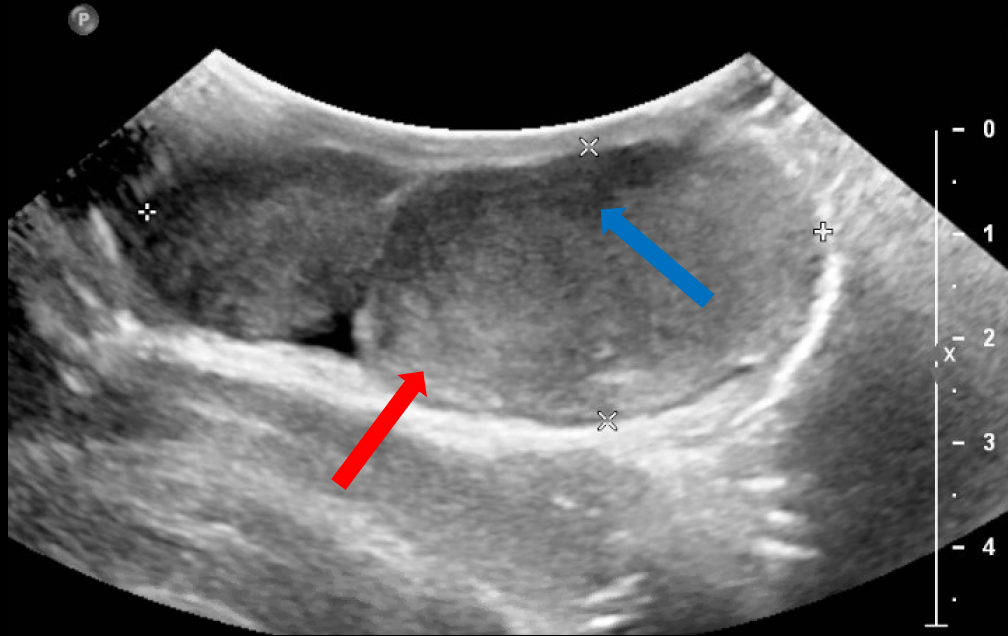
What Imaging Should We Order?

# Testicular Ultrasound with Color Doppler

# Testicular Ultrasound with Color Doppler



# Testicular Ultrasound with Color Doppler



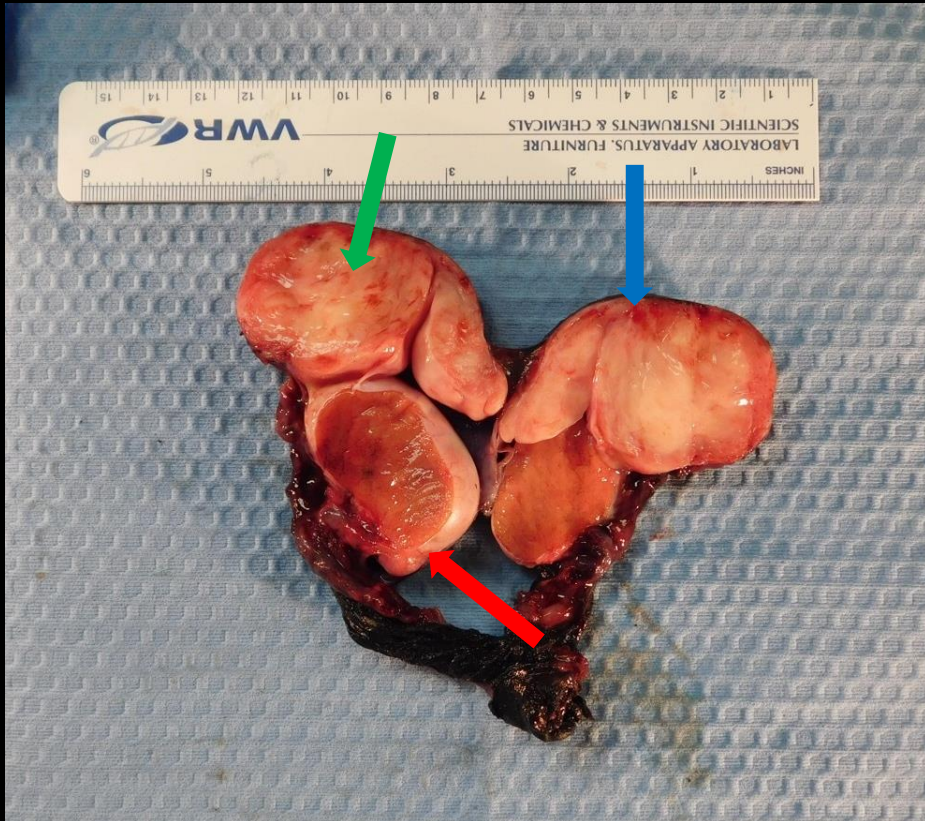
- Within the right hemiscrotum and inferior to the testes, there is a 6.5 cm bilobulated extratesticular mass with significant amount of internal vascularity (right image) and areas of both hyper- (red arrow) and hypoechogenicity (blue arrow). This favors a neoplastic process.
- Both images are in a sagittal orientation and show the right hemiscrotum.

# Differential Diagnoses

- Rhabdomyosarcoma
- Adenocarcinoma of rete testis or epididymis
- Mesothelioma of tunica vaginalis
- Testicular tumor (germ cell, sex cord stromal, mixed)

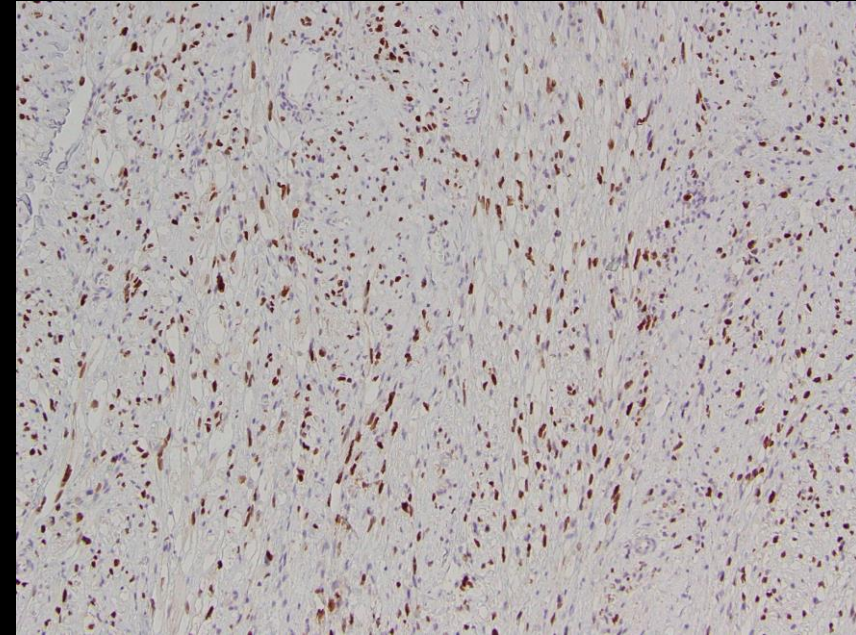
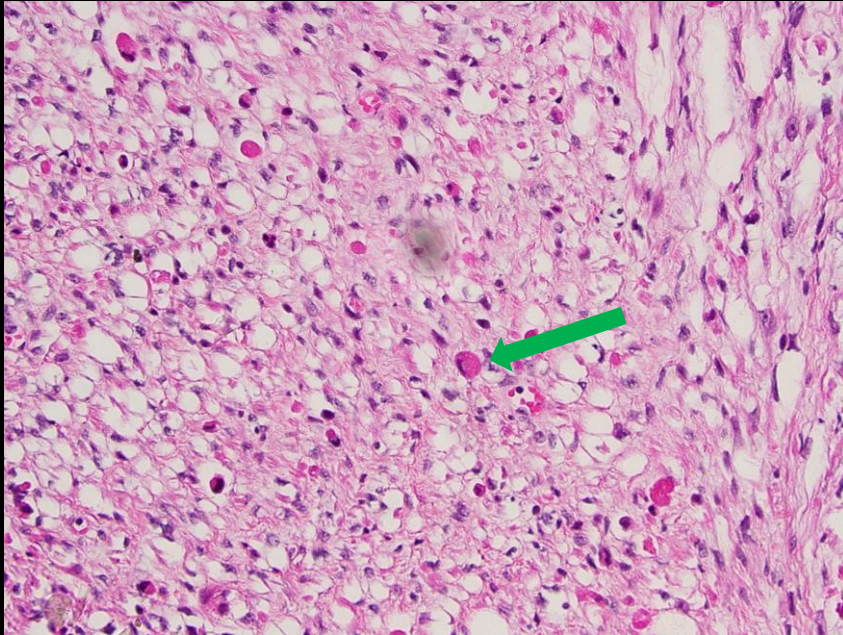


# Pathology (Gross)



- The specimen is a right radical orchiectomy
- The testicle appears normal and is surrounded by tunica albuginea (**red arrow**).
- The mass is tan-yellow in color and appears fleshy with areas of variegation (**green arrow**) and hemorrhage (**blue arrow**).

# Pathology (Microscopic)



- The microscopic image to the left appears neoplastic with a sheet of cells in a sweeping pattern. Strap cells (**green arrow**) are present and appear eosinophilic due to the presence of thick and thin filaments.
- The image to the right shows a positive myogenin stain.

Final Dx:

Right paratesticular rhabdomyosarcoma

# Case Discussion

- Rhabdomyosarcoma is the most common soft tissue tumor of childhood. The annual incidence is 4.3 cases per one million. It is slightly more common in males and in African Americans.
- It originates from immature cells that would eventually become skeletal muscle. Histologic staining for myogenin helps to confirm the diagnosis. Histology shows strap cells, which are eosinophilic cells with cytoplasm rich in thick and thin filaments.

# Case Discussion

- Four major histologic subtypes of rhabdomyosarcoma have been described; they help to identify optimal treatment and prognosis.
  - Embryonal: It is the most common subtype and carries an intermediate prognosis. It is composed of typical rhabdomyoblasts in sheets and nests.
  - Botryoid: It is named for its grape-like gross appearance. It grows beneath an epithelial surface as dense aggregates of rhabdomyoblasts. It is usually located along the bladder or vaginal wall and occurs in infants. It has a more favorable prognosis.
  - Alveolar: It is classified by having >50% alveolar architectural pattern and a FOXO1 rearrangement (t(1;13) or t(2;13)) . It has a relatively poor outcome.
  - Anaplastic: It has the worst prognosis. It has large, hyperchromatic nuclei and atypical mitotic figures. It is seen in patients with Li-Fraumeni syndr

# Case Discussion

- The clinical presentation of a rhabdomyosarcoma often depends on the anatomic site and presence or absence of metastasis.
- Common sites for the primary tumor to arise include the orbit, parameningeal, glands of the neck, bladder, prostate, genital tracts, and the extremities. Less than 25% of patients have distant metastasis, which most often occurs in the lung.
- Treatment depends on the estimated risk of disease recurrence, which is based on a multitude of clinical and pathological factors. Treatment typically consists of complete resection of the primary lesion, radiation therapy to enhance local control, and chemotherapy for primary tumor cytoreduction as well as elimination of macroscopic and microscopic metastatic disease.

# References

1. Dasgupta R, Fuchs J, Rodeberg D. Rhabdomyosarcoma. *Semin Pediatr Surg.* 2016;25(5):276-283. doi:10.1053/j.sempedsurg.2016.09.011
2. Annam, A, Munden, M.M., Mehollin-Ray, A.R. *et al.* Extratesticular masses in children: taking ultrasound beyond paratesticular rhabdomyosarcoma. *Pediatr Radiol* 45, 1382–1391 (2015).
3. Bromby A, Cresswell J (2014) Differential diagnosis of a scrotal mass. *Trends Urol Mens Health* 5(1):15–18.
4. Okcu M, Hicks J, Lupo P. Rhabdomyosarcoma in childhood and adolescence: Epidemiology, pathology, and molecular pathogenesis. In: UpToDate, Post, TW (Ed), UpToDate, Waltham, MA, 2020.