

AMSER Case of the Month: Malignant Pheochromocytoma

Alexis Violette, MS4

Medical University of South Carolina

Dr. Jeanne Hill, M.D. and Dr. Laura Spruill, M.D., Ph.D.

Medical University of South Carolina

Patient Presentation

- HPI:
 - 66 y.o. female with PMHx of uncontrolled hypertension, type 2 diabetes, hyperlipidemia, and unintentional 15-pound weight loss presented to the ED with shortness of breath and concern for PE. A CT scan was negative for PE, but incidentally noted a right adrenal mass.
- Physical exam:
 - BP 184/98, HR 112, T 99, O₂ 100% on RA
 - Tachycardic; no murmurs, rubs, or gallops; lungs clear bilaterally; abdomen soft, nontender, nondistended without palpable masses; left supraclavicular lymphadenopathy present

Pertinent Labs

- CBC and CMP within normal limits except for glucose of 198 mg/dL
- Plasma free metanephrines: 750 pg/mL (normal range 12 – 60 pg/mL)
- Plasma free normetanephrines: 8395 pg/mL (normal range 18 – 111 pg/mL)

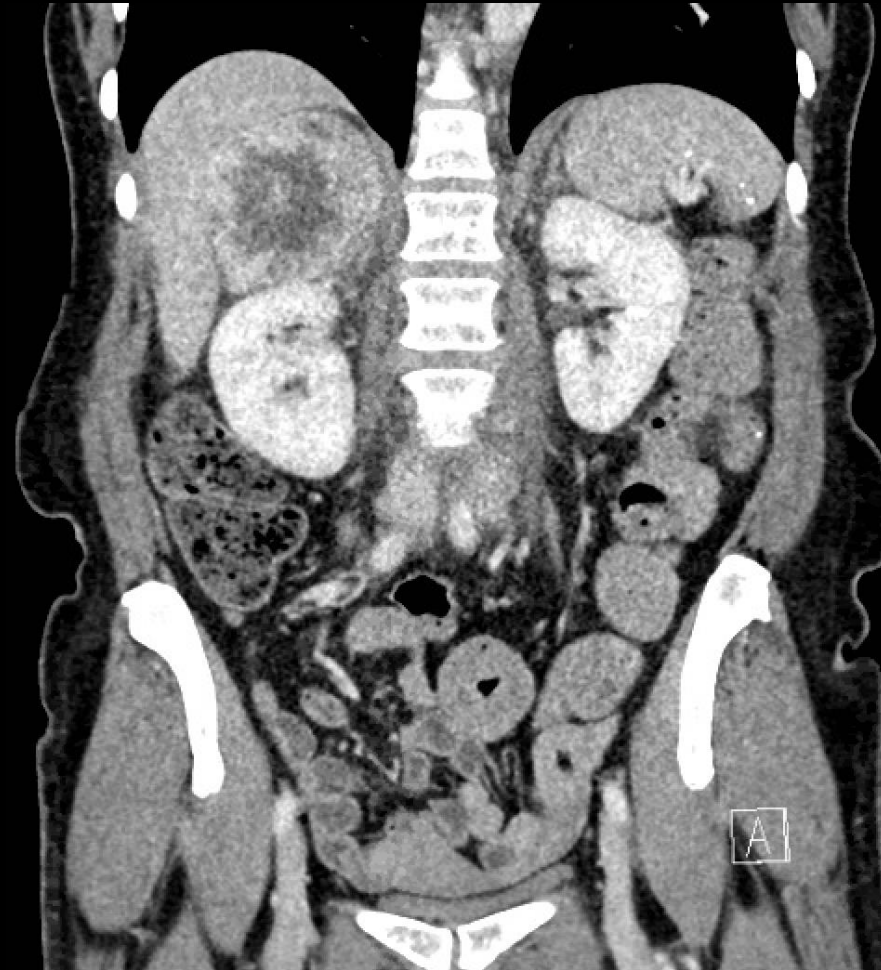
What Imaging Should We Order?

Clinical Condition: Incidentally Discovered Adrenal Mass

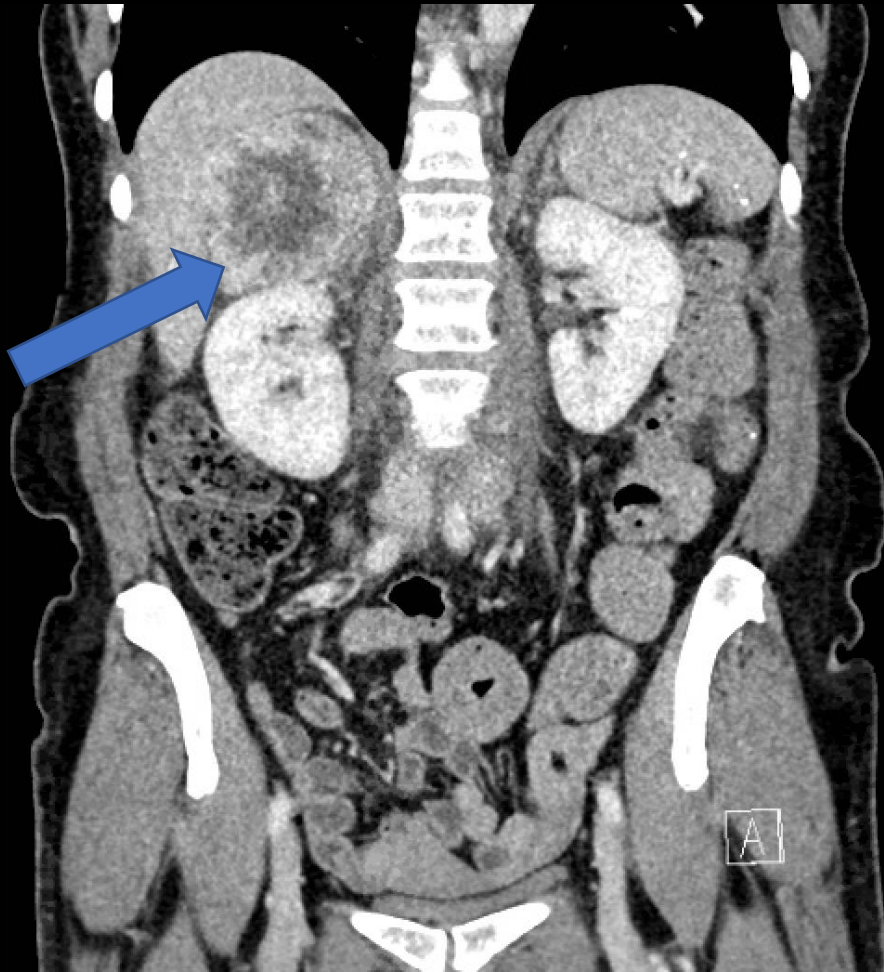
Variant 3: No history of malignancy; mass >4 cm in diameter. (If not typical for adenoma, myelolipoma, hemorrhage, or simple cyst, consider resection.)

Radiologic Procedure	Rating	Comments	RRL*
CT abdomen with IV contrast	8	As part of preoperative staging. Alternative to MRI.	☼☼☼
MRI abdomen without and with IV contrast	8	As part of preoperative staging. Alternative to CT.	0
FDG-PET/CT skull base to mid-thigh	5	As part of preoperative staging.	☼☼☼☼
MIBG	2	Only for suspicion of pheochromocytoma.	☼☼☼
CT abdomen without and with IV contrast	2		☼☼☼☼
MRI abdomen without IV contrast	1		0
US adrenal gland	1		0
CT abdomen without IV contrast	1		☼☼☼
X-ray abdomen	1		☼☼
Iodocholesterol scan	1	This agent may be used to detect functionally active adenomas.	☼☼☼☼
Biopsy adrenal gland	1		Varies
<u>Rating Scale:</u> 1,2,3 Usually not appropriate; 4,5,6 May be appropriate; 7,8,9 Usually appropriate			*Relative Radiation Level

CT Abdomen and Pelvis with Contrast

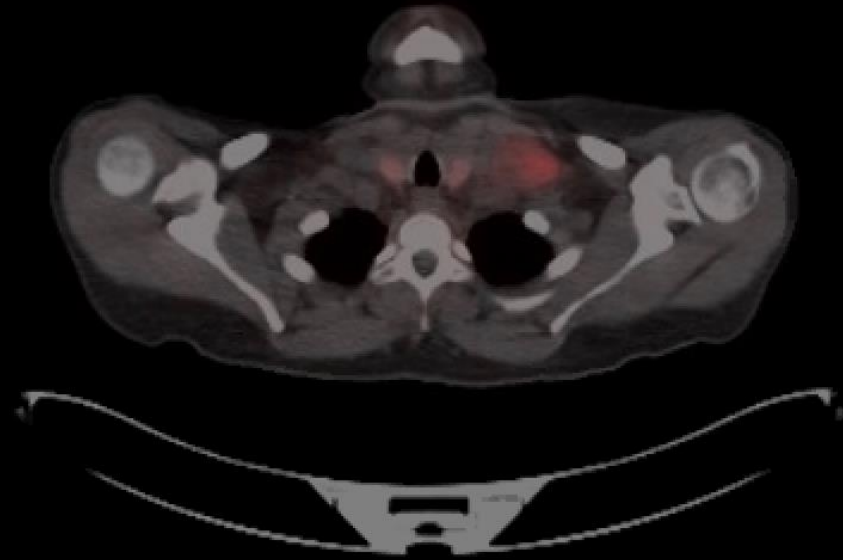
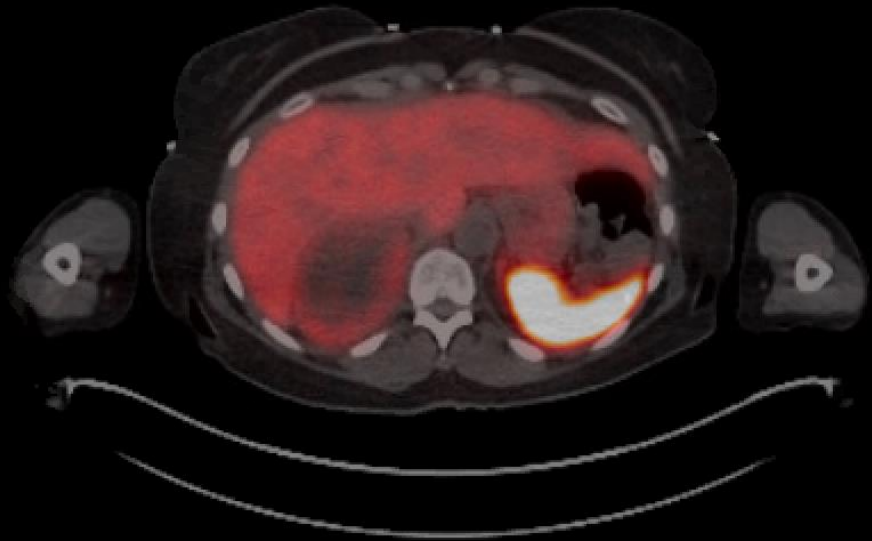


CT Abdomen and Pelvis with Contrast



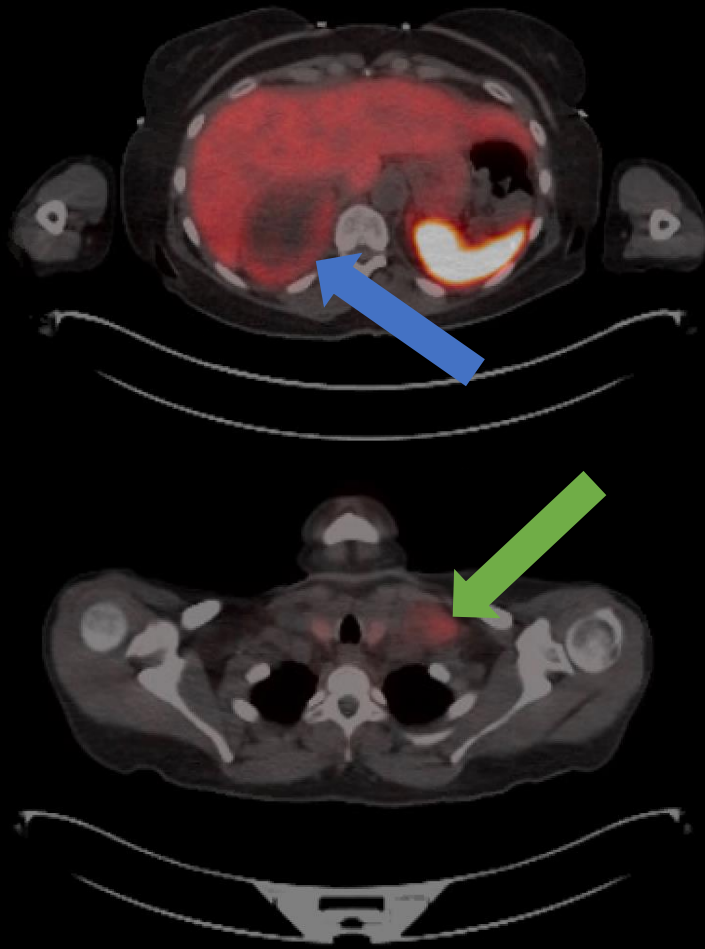
- CT demonstrates large, centrally necrotic mass arising from the right adrenal gland (blue arrow). It measures 8.3 x 6.5 cm.
- There are calcified granulomas in the spleen. Kidneys, GI tract, vasculature, urinary bladder, and pelvic reproductive organs are unremarkable.

PET CT



- This was ordered to assess both the adrenal mass and the supraclavicular lymphadenopathy for hypermetabolic activity, as well as for surgical planning.

PET CT

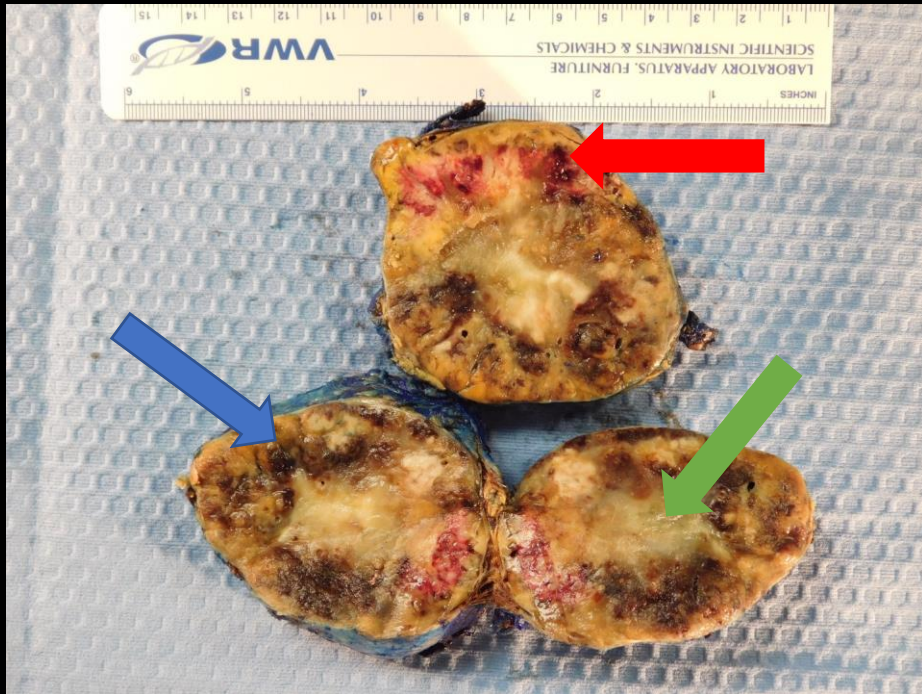


- There is a large, centrally necrotic mass with peripheral radiotracer activity equal to that of the liver (blue arrow). There is also a large, left supraclavicular lymph node, measuring up to 3.4 cm, with radiotracer uptake equal to or less than that of the liver (green arrow). It is likely indicative of metastasis.

Differential Diagnoses for Adrenal Mass

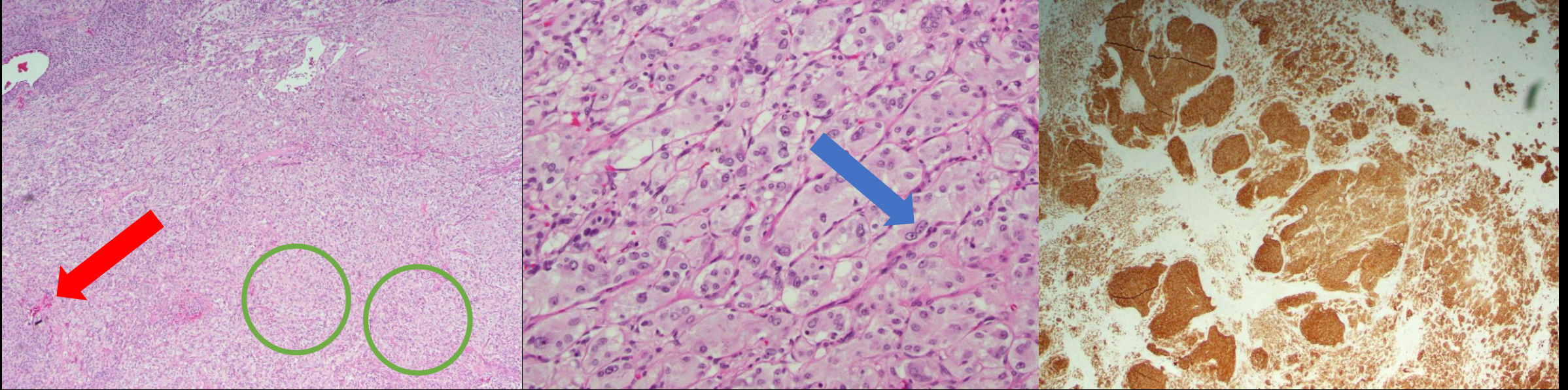
- Pheochromocytoma
- Adrenocortical carcinoma
- Metastasis
- Adrenal adenoma (unlikely given hypermetabolic activity on PET CT)

Pathology (Gross)



- The specimen is a right adrenalectomy. The cut section is shown to the left.
- There are areas of mahogany brown (blue arrow), hemorrhage (red arrow), and tissue necrosis (green arrow). This is indicative of aggressive behavior of the tumor.

Pathology (Microscopic)



- The low power image to the left shows nested neuroendocrine cells (**green circle**) with areas of hemorrhage (**red arrow**).
- The high power image in the center shows pleomorphism of neuroendocrine cell nuclei, with varying sizes and multiple nucleoli (**blue arrow**).
- The image to the right shows a positive synaptophysin stain.

Final Dx:

Malignant Pheochromocytoma

Case Discussion

- A pheochromocytoma is a catecholamine-secreting neuroendocrine tumor that arises from chromaffin cells of the adrenal medulla. They are rare, with an annual incidence of 0.8 per 100,000 person years.
- Most tumors are sporadic, but 40% are diagnosed in the context of familial disorders (VHL, MEN2, NF1). These disorders have autosomal dominant inheritance, so there is generally a pertinent family history.
- The patient will likely have a history of HTN, headaches, sweating, palpitations, and dyspnea. Symptoms are often episodic and can be mistaken for panic attacks. They are a direct result of catecholamine release, which can also lead to abnormalities in carbohydrate metabolism leading to an apparent DM2.

Case Discussion

- When a pheochromocytoma is suspected, the initial workup consists of urinary and plasma metanephrines and catecholamines. If the patient is at a low risk for pheochromocytoma, 24-hour urine fractionated metanephrines and catecholamines is the suggested test. If the patient is at high risk, plasma fractionated metanephrines is suggested.
- The next best step in management is imaging via CT or MRI to locate the tumor. Any site containing paraganglionic tissue can be involved; other than the adrenals, common sites include paraaortic, urinary bladder, and the thorax.

Case Discussion

- Treatment of a pheochromocytoma consists of surgical removal of the tumor. Preoperatively, an alpha-adrenergic blocker is given for 7 days in order to control blood pressure and to expand the intravascular space.
 - Phenoxybenzamine is most commonly used due to its irreversible and long-acting properties.
- On day 2-3 of alpha blockade, the patient is advised to initiate a high sodium diet to further aid in volume expansion.
- Two days prior to the surgery, the patient should begin taking a beta-adrenergic blockade.
 - The beta blockade should never be initiated before the alpha blockade due to the risk for hypertensive emergency.

Case Discussion

- Once the tumor is removed, it is examined histologically, which will show nests of neuroendocrine cells that stain positive for synaptophysin, a glycoprotein involved with the neuroendocrine secretory granule membrane.
- Pheochromocytomas are also evaluated via PASS scoring and a score of 4 or less favors less aggressive behavior. The PASS score depends on many factors including nuclear pleomorphism, capsule or vascular invasion, atypical mitotic figures, cellularity, and necrosis. This patient had a PASS score of 15, which is predicted to be biologically aggressive.

References

- Leung K, Stamm M, Raja A, Low G. Pheochromocytoma: the range of appearances on ultrasound, CT, MRI, and functional imaging [published correction appears in *AJR Am J Roentgenol*. 2013 Mar;200(3):705]. *AJR Am J Roentgenol*. 2013;200(2):370-378. doi:10.2214/AJR.12.9126
- Blake MA, Kalra MK, Maher MM, et al. Pheochromocytoma: an imaging chameleon. *Radiographics*. 2004;24 Suppl 1:S87-S99. doi:10.1148/rg.24si045506
- Thompson LD. Pheochromocytoma of the Adrenal gland Scaled Score (PASS) to separate benign from malignant neoplasms: a clinicopathologic and immunophenotypic study of 100 cases. *Am J Surg Pathol*. 2002;26(5):551-566. doi:10.1097/00000478-200205000-00002
- Young W, Kebebew E. Treatment of pheochromocytoma in adults. In: UpToDate, Post, TW (Ed), UpToDate, Waltham, MA, 2020.
- Young W. Clinical presentation and diagnosis of pheochromocytoma. In: UpToDate, Post, TW (Ed), UpToDate, Waltham, MA, 2020.