

AMSER Case of the Month: May 2019



64 y.o. male with back pain



Allegheny
Health Network

Bryan Farnsworth, OMS III

Lake Erie College of Osteopathic Medicine

Matthew Hartman, M.D.

Allegheny Health Network

Medical Student Clerkship Director



Patient Presentation

- 64 y.o. male presents with bilateral, non-radiating, lower back pain for a few days with nausea and increased urinary frequency. Denies SOB, chest pain, vomiting, changes in weight, fever, and chills.
- PMHx: OA of the knees
- SHx: 40 pack-year Hx of smoking; quit 4 years ago.
- FH: Father had an AAA
- BP 184/122 | P 110 | T 97.6 | RR 18 | SpO2 97%
- Physical Exam: palpable pulsatile abdominal mass, lumbar paraspinal and flank tenderness and equal pedal pulses bilaterally.

What Imaging Should We Order?

Select the applicable ACR Appropriateness Criteria

**American College of Radiology
ACR Appropriateness Criteria®
Pulsatile Abdominal Mass, Suspected Abdominal Aortic Aneurysm**

Variant 1: Pulsatile abdominal mass, suspected abdominal aortic aneurysm.

Radiologic Procedure	Rating	Comments	RRL*
US aorta abdomen	9		0
CTA abdomen with IV contrast	8		☼☼☼
MRA abdomen without and with IV contrast	8		0
CT abdomen without IV contrast	7		☼☼☼
CT abdomen with IV contrast	7		☼☼☼
CT abdomen without and with IV contrast	7		☼☼☼☼
MRA abdomen without IV contrast	7		0
Aortography abdomen	4		☼☼☼
FDG-PET/CT abdomen	2		☼☼☼☼

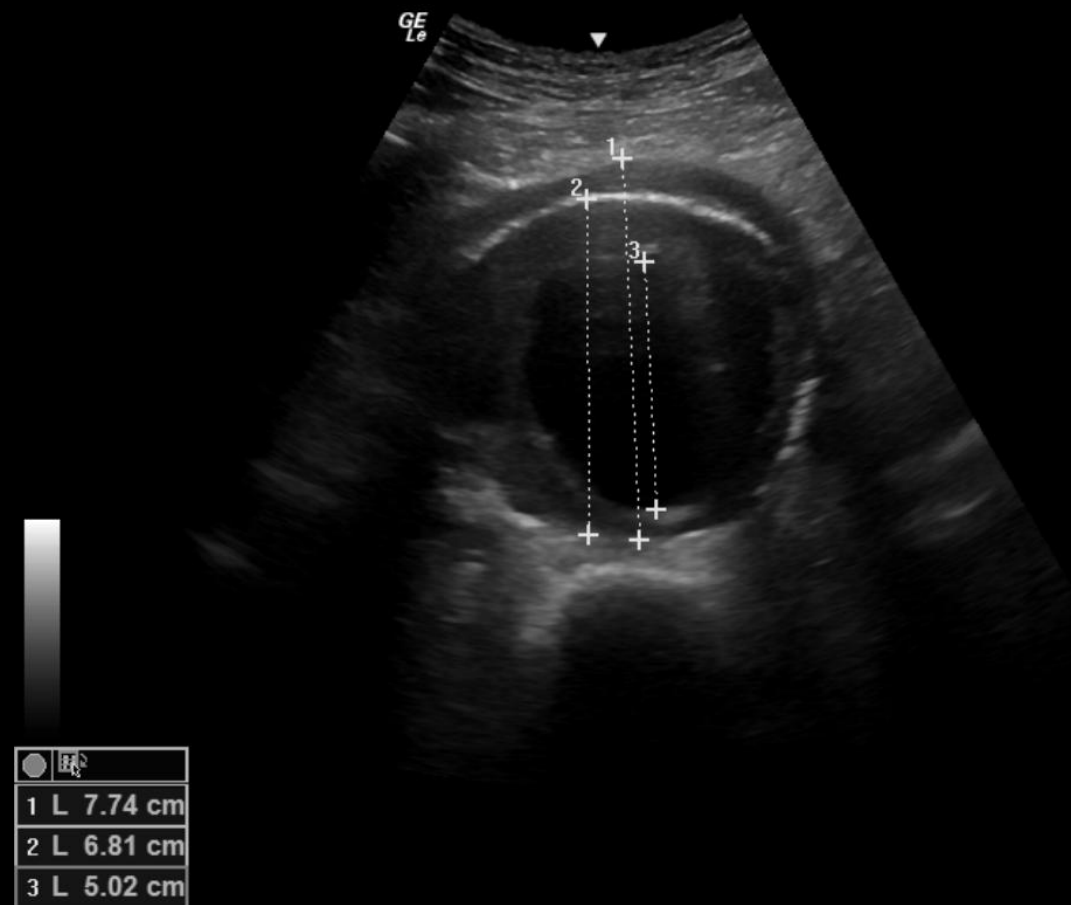
Rating Scale: 1,2,3 Usually not appropriate; 4,5,6 May be appropriate; 7,8,9 Usually appropriate

*Relative Radiation Level

This imaging modality was performed by the ER physician

This imaging modality was later ordered.

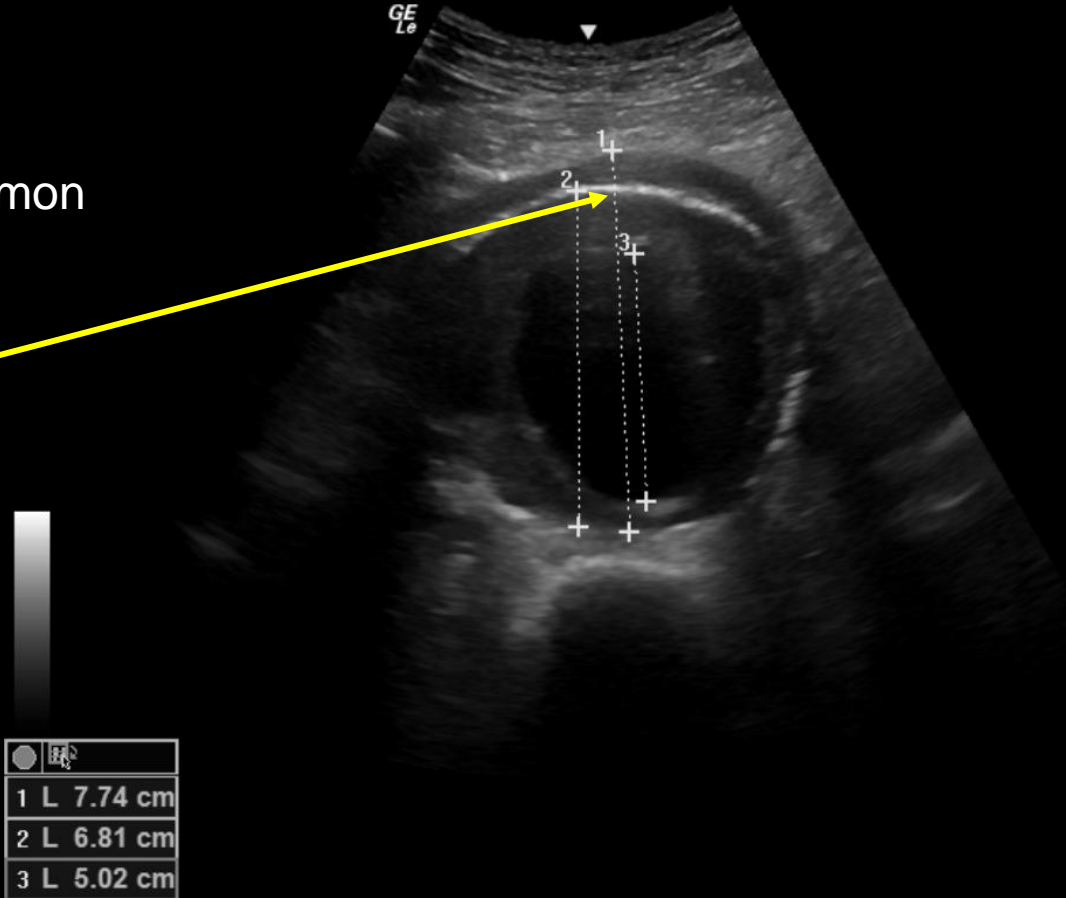
Limited US of abdominal aorta performed by ED physician



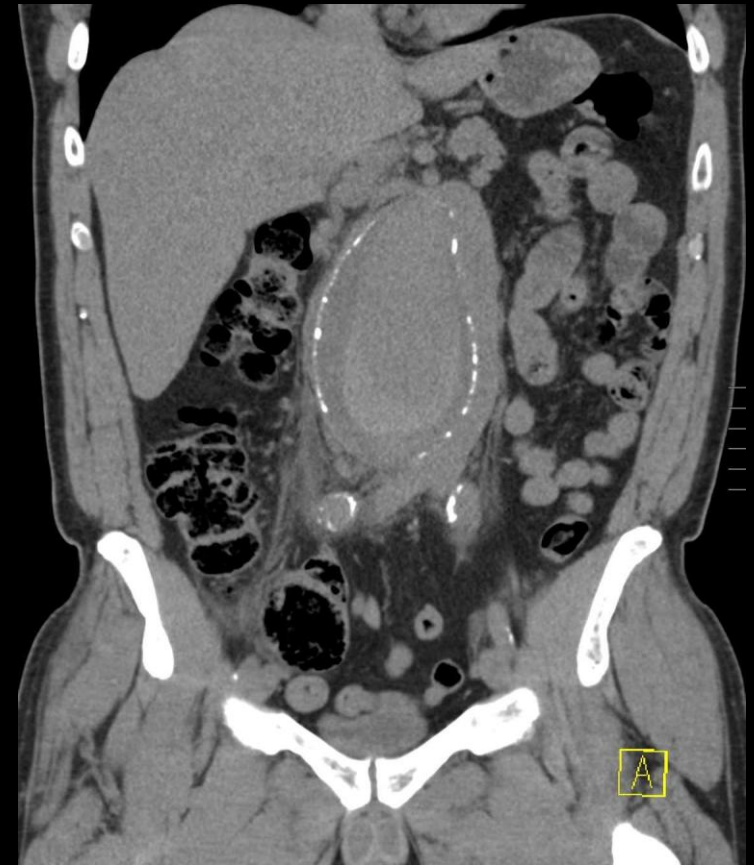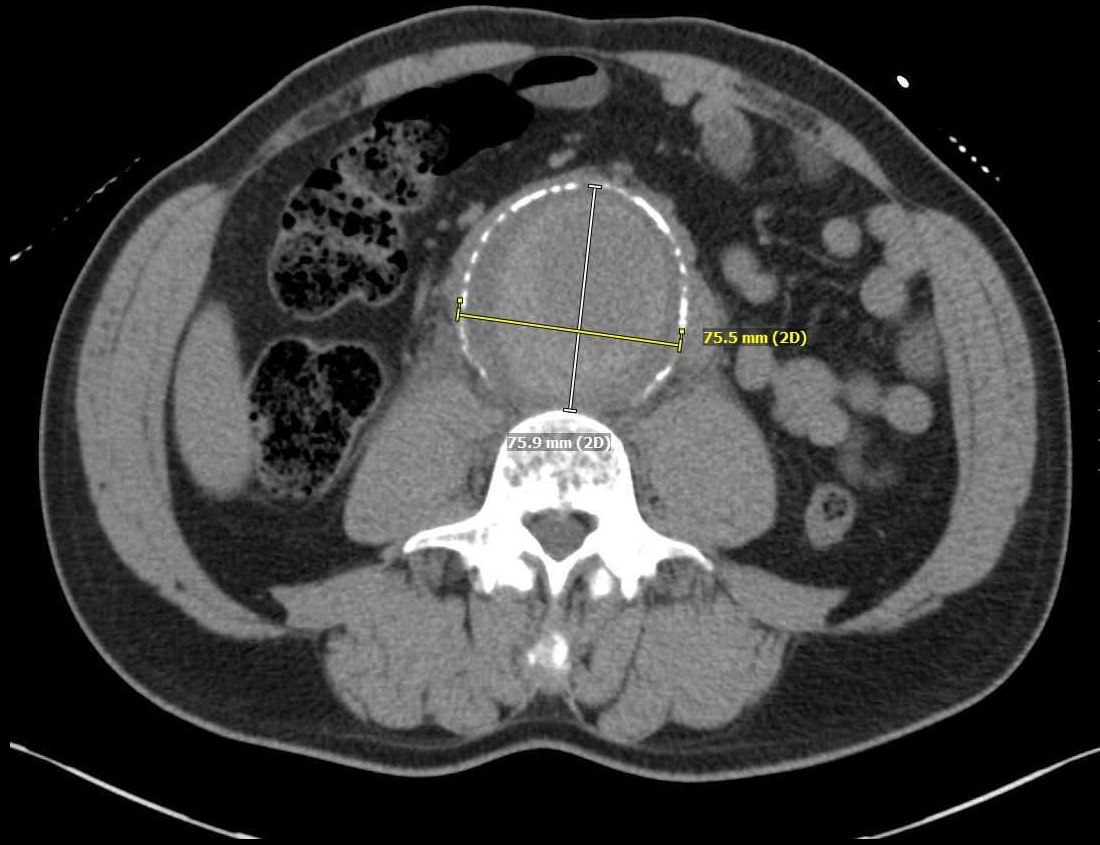
Limited US of abdominal aorta performed by ED physician

- Abdominal aorta visualized SMA to proximal common iliac artery

Dilation to nearly 8cm



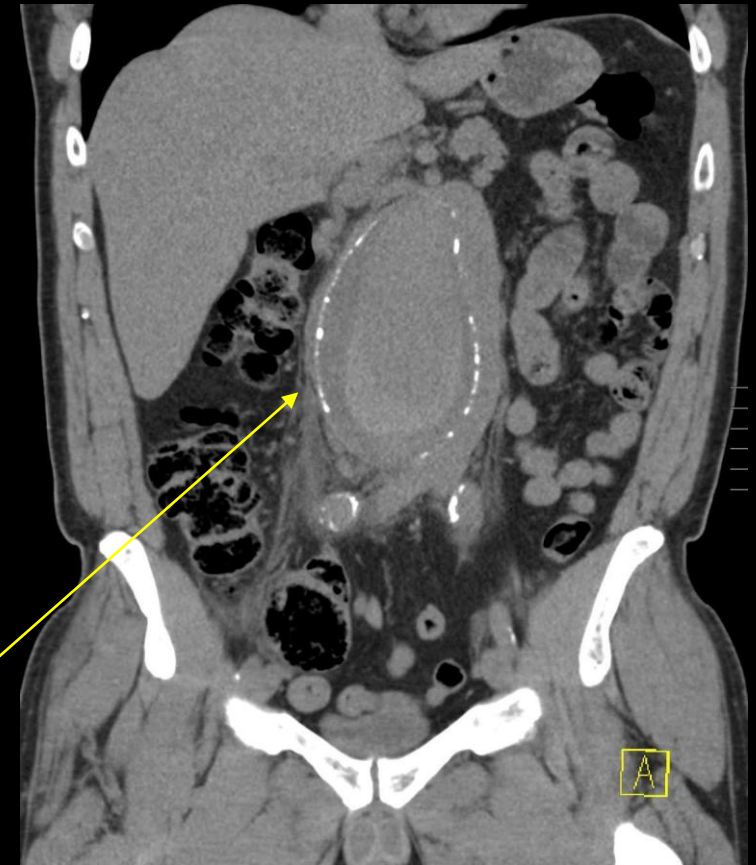
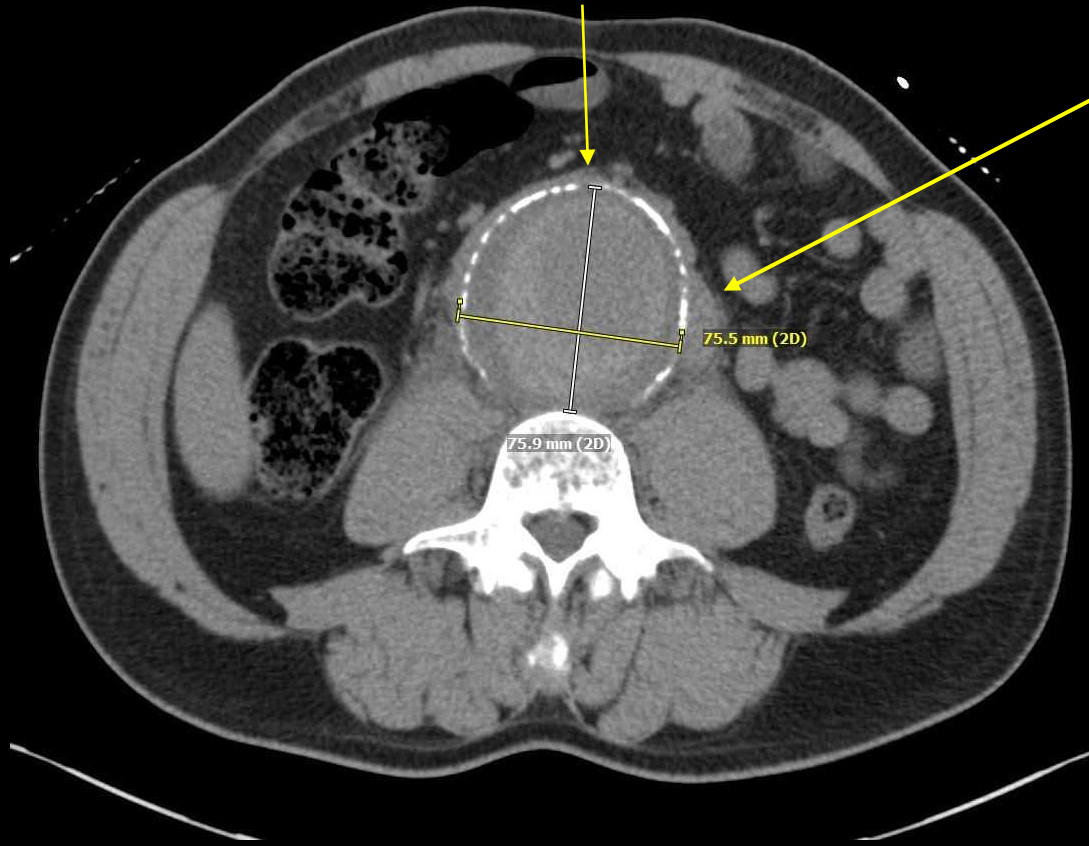CT abdomen without contrast



CT abdomen without contrast

Dilation of abdominal aorta

Left sided IVC



Periaortic fat stranding concerning for impending rupture


Final Dx:

Symptomatic non-ruptured abdominal aortic aneurysm

Abdominal Aortic Aneurysm (AAA)

- Average diameter of abdominal aorta is ~2cm; ≥ 3 cm or $> 1.5x$ normal section of aorta is considered aneurysmal
- Risk factors:
 - Smoking history, advanced age, male gender, atherosclerosis, Caucasian race, family history of AAA and connective tissue disorders
- Presentation:
 - Most patients are asymptomatic and AAA is found incidentally or through screening; If symptomatic, typical presentation is abdominal pain, back pain or flank pain.
 - Physical signs of rupture may include hypotension and flank ecchymosis

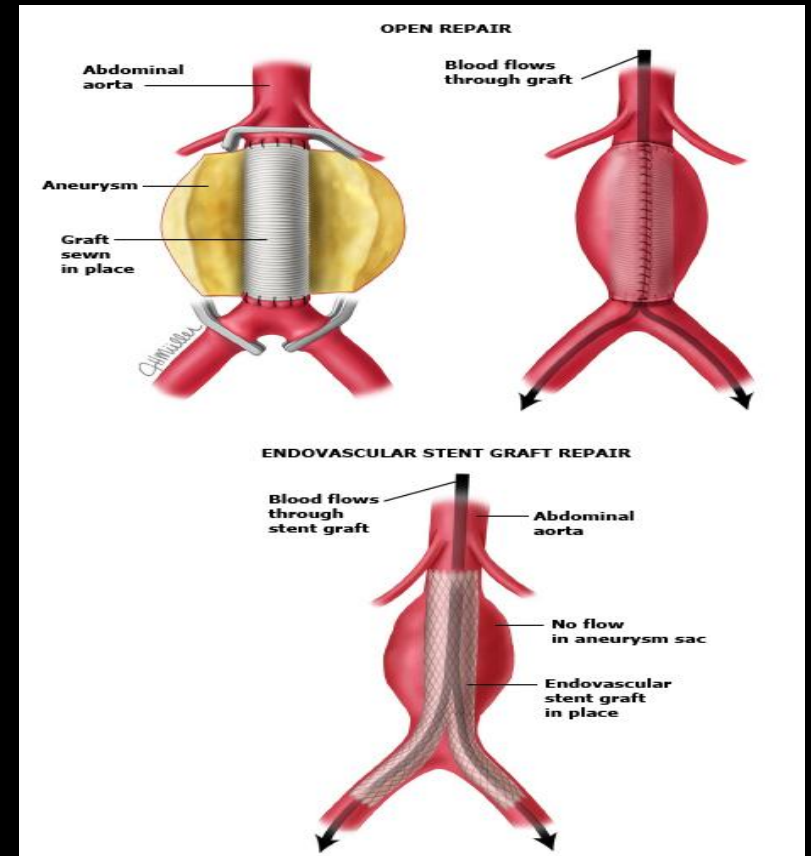
Abdominal Aortic Aneurysm (AAA)

- Risk factors for rupture
 - current smoking, elevated blood pressure, increased rate of expansion (>0.5 cm/ yr) and symptomatic presentation.
- Signs of impending vs complete rupture on imaging 

Location	Imaging findings	Complete rupture	Impending rupture
Intramural	Increased aneurysm size	-	+
	Rapid enlargement rate	-	+
	Focal wall discontinuity	+	+
	Hyperattenuating crescent sign	-	+
	Thrombus fissuration	-	+
	Draped aorta sign	-	+
Luminal	Aortoenteric fistula	+	-
	Aortocaval fistula	+	-
Extraluminal	Periaortic stranding	-	+
	Contrast extravasation	+	-
	Retroperitoneal haematoma	+	-
	Intraperitoneal haematoma	+	-

AAA Management and Patient Outcome

- Management
 - If AAA has ruptured, emergent repair should be initiated
 - If AAA is symptomatic, but without rupture, urgent surgical repair is advised
 - If AAA is asymptomatic
 - If <5.5 cm intervention is not usually indicated
 - If ≥ 5.5 cm elective repair should be considered.
- Repair options include endovascular or open repair
 - Patient successfully underwent open repair without complications



References:

- American College of Radiology. ACR Appropriateness Criteria®. Available at <https://acsearch.acr.org/docs/69414/Narrative/> Accessed March 09, 2019
- Keisler, Brian, and Chuck Carter. “Abdominal Aortic Aneurysm.” AAFP Home, 15 Apr. 2015, www.aafp.org/afp/2015/0415/p538.html.
- UpToDate. <https://www.uptodate.com/contents/overview-of-abdominal-aortic-aneurysm/> Accessed March 09, 2019
- Vu, Kim-Nhien et al. “Rupture signs on computed tomography, treatment, and outcome of abdominal aortic aneurysms” Insights into imaging vol. 5,3 (2014): 281-93.