

AMSER Case of the Month

August 2019

29 year-old female who presents for molar pregnancy

Christian Gomez MS4

Drexel University College of Medicine

Dr. Matthew Hartman MD, Department of Radiology

Dr. Eirwen Miller MD, Division of Gynecologic Oncology



Allegheny Health Network



Patient Presentation

- Patient is a 29 year-old G2P1011 who presents for follow-up concerning her recent diagnosis of a **complete molar pregnancy** s/p with dilation and curettage 1 month ago. Since her procedure, she has had **occasional spotting**.
- Past Medical History: None
- Social History: Denies tobacco/alcohol/drugs
- Surgical History: Breast implantation

Pertinent Labs

- Physical Exam: GU – there is no rash on either the right or left labia. **Uterus is tender.** Cervix exhibits no motion tenderness and no discharge. Right adnexum displays no mass and no tenderness. Left adnexum displays no mass and no tenderness. No bleeding in the vagina
- Vitals: T 36.7 °C R 69 bpm BP 103/69 mmHg
 RR 16 SpO₂ 100%

Labs:

hCG at diagnosis of molar pregnancy (1.5 mo ago): **109,489**

hCG 3 weeks ago: **4171.0**

hCG 1 week ago: **4928.0**

hCG today: **7600.0**

What Imaging Should We Order?

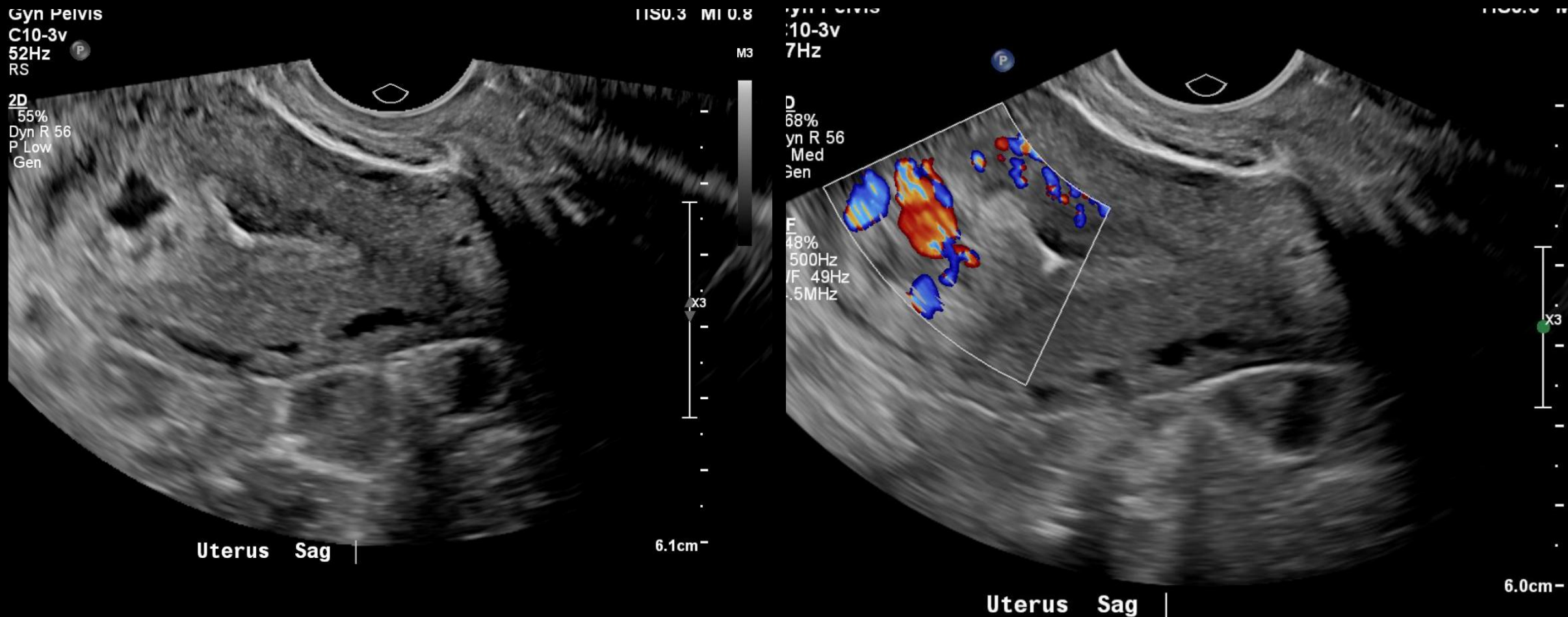
ACR Appropriateness Criteria for risk assessment of Gestational Trophoblastic Neoplasia (GTN)

Variant 2: Staging and risk assessment: suspected or established diagnosis of gestational trophoblastic neoplasia (GTN).

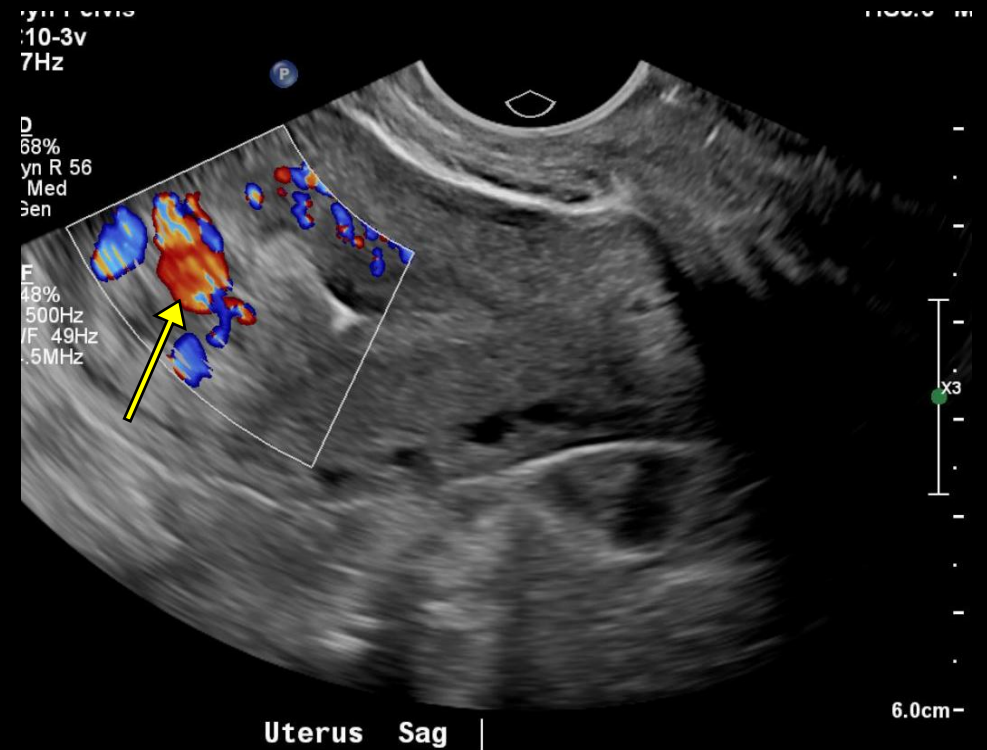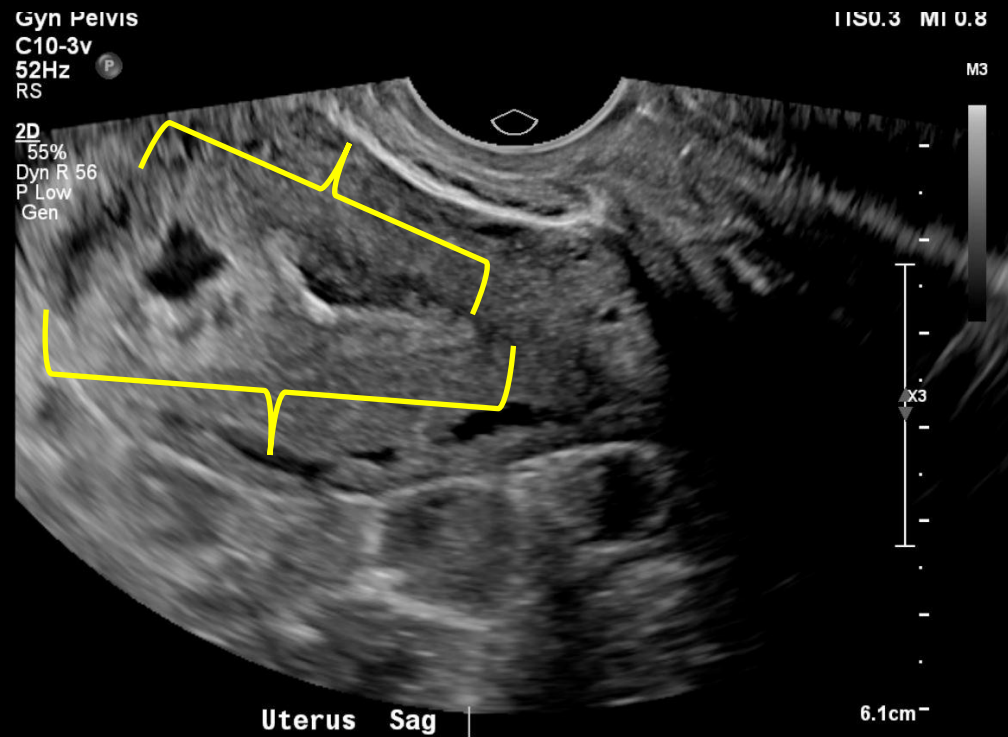
Procedure	Appropriateness Category	Relative Radiation Level
US pelvis transvaginal	Usually Appropriate	○
Radiography chest	Usually Appropriate	⊕
US duplex Doppler pelvis	Usually Appropriate	○
US pelvis transabdominal	Usually Appropriate	○
CT abdomen and pelvis with IV contrast	Usually Appropriate	⊕⊕⊕
CT chest with IV contrast	Usually Appropriate	⊕⊕⊕
MRI pelvis without and with IV contrast	Usually Appropriate	○
MRI head without and with IV contrast	May Be Appropriate	○
CT chest without IV contrast	May Be Appropriate	⊕⊕⊕
CT head with IV contrast	May Be Appropriate	⊕⊕⊕
FDG-PET/CT skull base to mid-thigh	May Be Appropriate	⊕⊕⊕⊕
MRI pelvis without IV contrast	May Be Appropriate (Disagreement)	○
CT abdomen and pelvis without and with IV contrast	Usually Not Appropriate	⊕⊕⊕⊕
MRI head without IV contrast	Usually Not Appropriate	○
CT abdomen and pelvis without IV contrast	Usually Not Appropriate	⊕⊕⊕
CT chest without and with IV contrast	Usually Not Appropriate	⊕⊕⊕
CT head without and with IV contrast	Usually Not Appropriate	⊕⊕⊕
CT head without IV contrast	Usually Not Appropriate	⊕⊕⊕

← Initial Imaging

Transvaginal Ultrasound (Unlabeled)



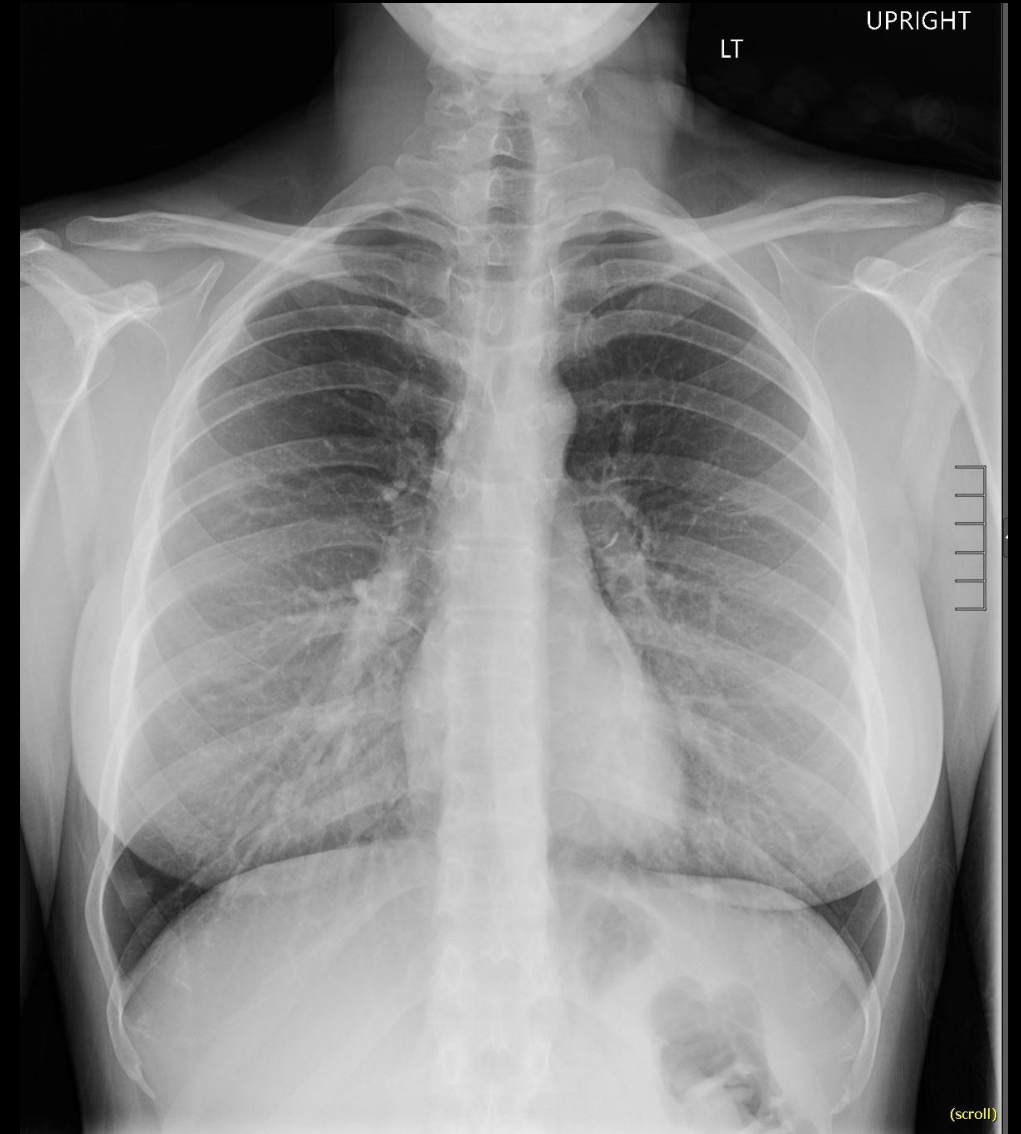
Transvaginal Ultrasound (Labeled)



- Thickened (brackets) , hypervascular (yellow arrow) endometrial stripe
- No evidence of intrauterine pregnancy

Chest X-Ray Results

- No disease is noted on Chest X-ray



Case Continued

- Given the imaging findings and rising hCG, a diagnosis of gestational trophoblastic neoplasia was made and another uterine evacuation was performed
- Pathology results were diagnostic for choriocarcinoma

What Additional Imaging Should We Order?

ACR Appropriateness Criteria for Staging GTN

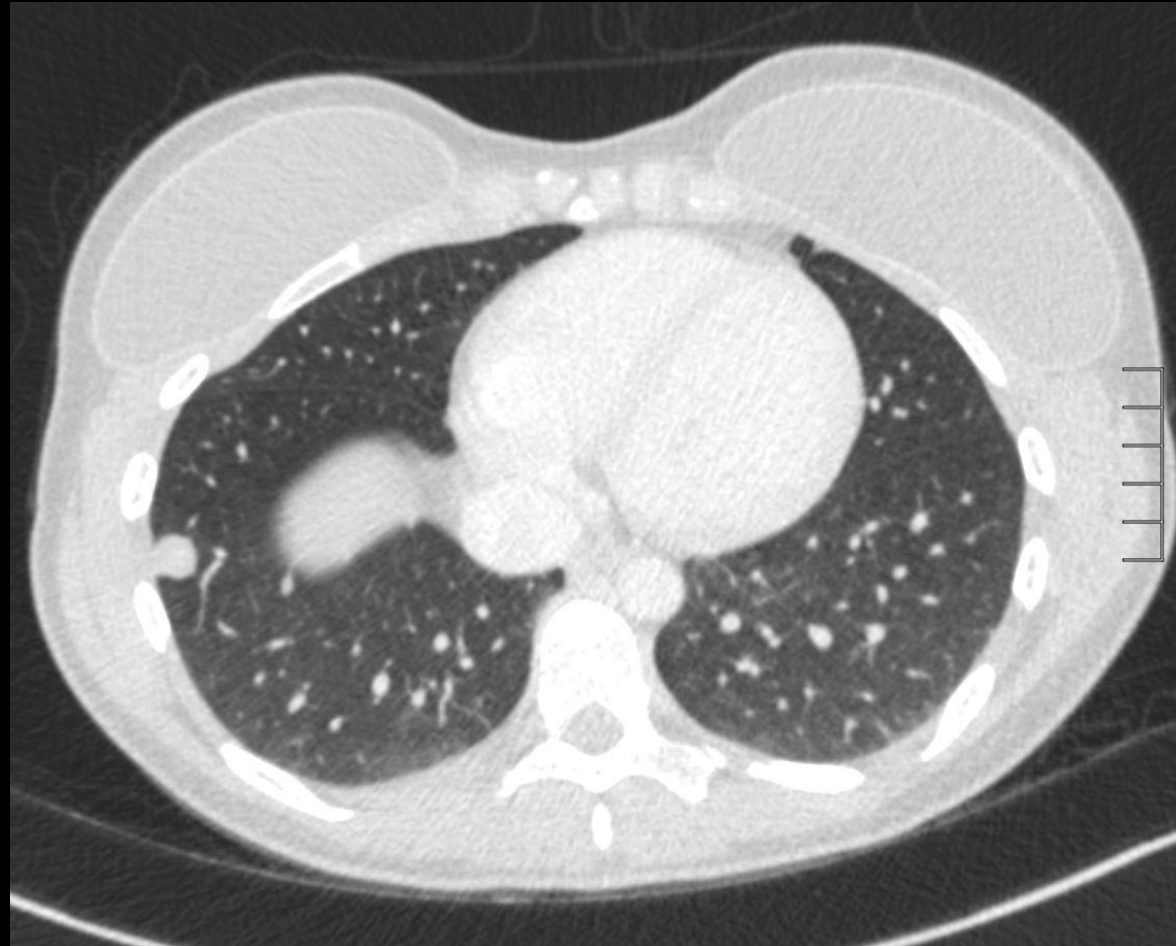
Variant 2: Staging and risk assessment: suspected or established diagnosis of gestational trophoblastic neoplasia (GTN).

Procedure	Appropriateness Category	Relative Radiation Level
US pelvis transvaginal	Usually Appropriate	0
Radiography chest	Usually Appropriate	⊕
US duplex Doppler pelvis	Usually Appropriate	0
US pelvis transabdominal	Usually Appropriate	0
CT abdomen and pelvis with IV contrast	Usually Appropriate	⊕⊕⊕
CT chest with IV contrast	Usually Appropriate	⊕⊕⊕
MRI pelvis without and with IV contrast	Usually Appropriate	0
MRI head without and with IV contrast	May Be Appropriate	0
CT chest without IV contrast	May Be Appropriate	⊕⊕⊕
CT head with IV contrast	May Be Appropriate	⊕⊕⊕
FDG-PET/CT skull base to mid-thigh	May Be Appropriate	⊕⊕⊕⊕
MRI pelvis without IV contrast	May Be Appropriate (Disagreement)	0
CT abdomen and pelvis without and with IV contrast	Usually Not Appropriate	⊕⊕⊕⊕
MRI head without IV contrast	Usually Not Appropriate	0
CT abdomen and pelvis without IV contrast	Usually Not Appropriate	⊕⊕⊕
CT chest without and with IV contrast	Usually Not Appropriate	⊕⊕⊕
CT head without and with IV contrast	Usually Not Appropriate	⊕⊕⊕
CT head without IV contrast	Usually Not Appropriate	⊕⊕⊕

Follow-up Imaging

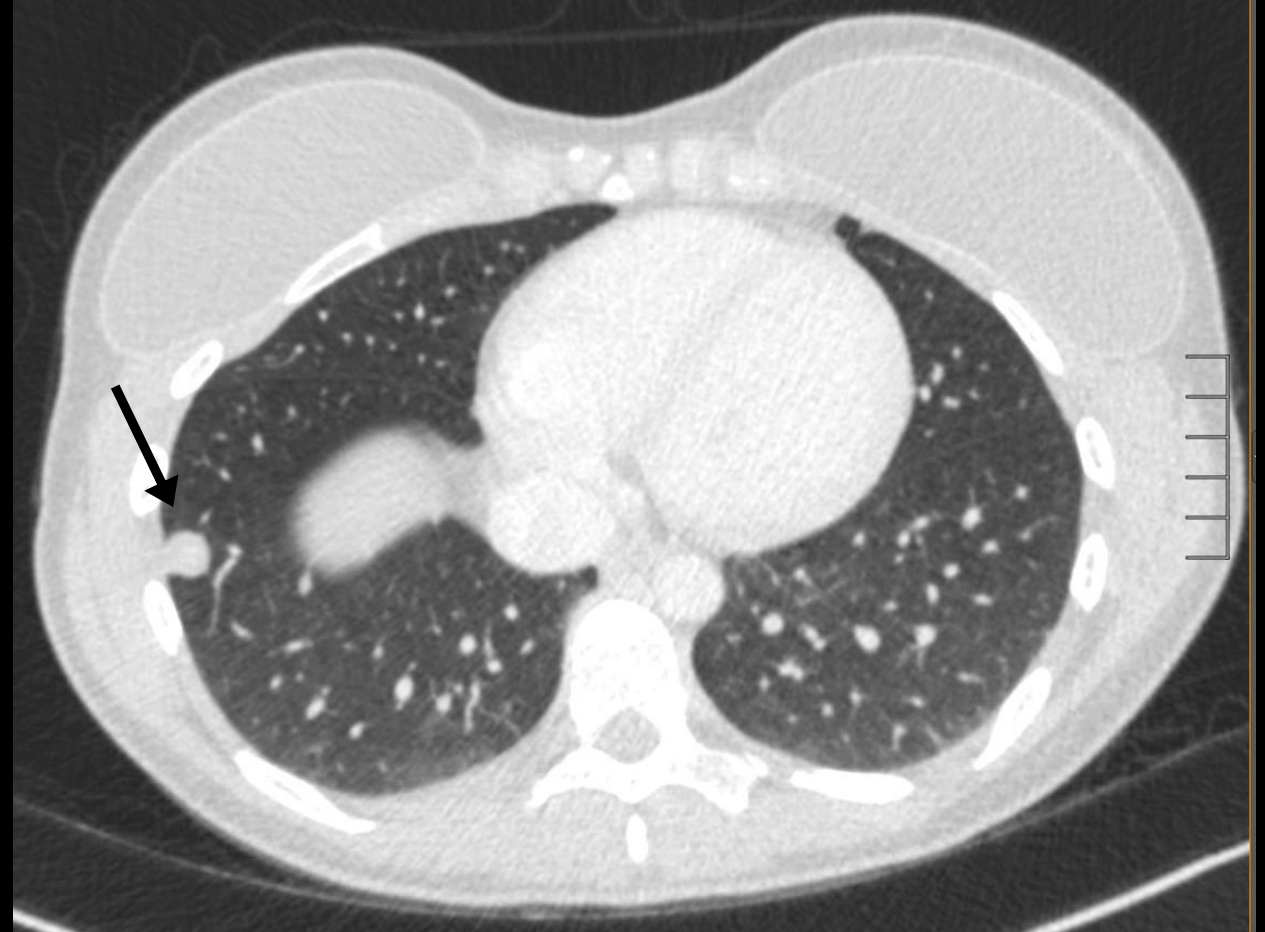


CT Chest Findings (Unlabeled)



CT Chest Findings (Labeled)

- Multiple pulmonary nodules were identified in bilateral lung fields. The largest (1.1 cm) is located in the right lower lobe (black arrow).



Final Diagnosis:
Choriocarcinoma

Differential Diagnosis:

- Invasive mole
- Choriocarcinoma
- Placental site trophoblastic tumor
- Epithelioid trophoblastic tumor

Choriocarcinoma – Epidemiology and Signs and Symptoms

Epidemiology

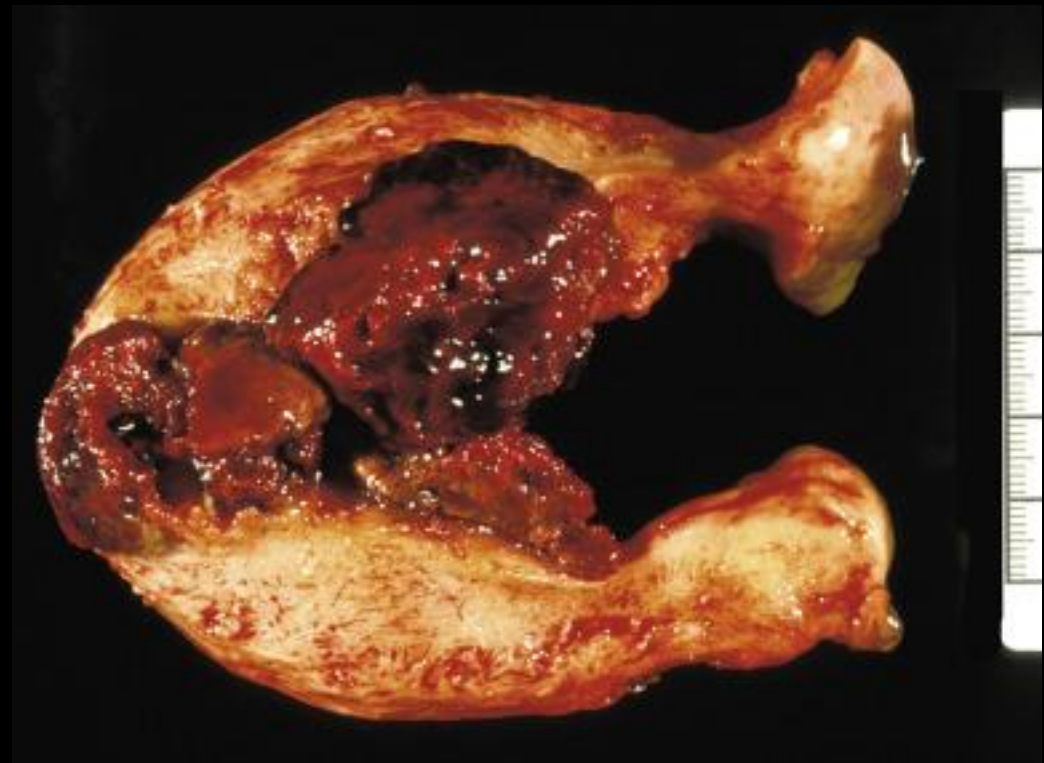
- Limited Information
- Incidence:
 - Idiopathic: 1 in 40,000
 - Previous molar pregnancy: 1 in 40
 - East and Southeast Asia has a higher incidence (3.3 in 40,000)
- Risk Factors
 - Advanced maternal age
 - Prior complete molar pregnancy
 - Ethnicity: Asian, American Indians, African Americans

Signs and symptoms

- Presents with irregular bleeding or rising HCG following postmolar evacuation
- May have enlarged, irregular uterus with bilateral adnexal enlargement
- Metastatic disease may cause symptoms associated with affected organ

Etiology of Choriocarcinoma

- Origin from placental trophoblast
 - Abnormal hyperplasia and anaplasia
 - Absent villi
 - May demonstrate hemorrhage or necrosis
 - Invades myometrium
- Hematogenous spread to distant sites – lung, brain, liver, and vagina



Crum, Christopher P., et al. *Diagnostic Gynecologic and Obstetric Pathology E-Book*. Elsevier Health Sciences, 2017.

Diagnosis and Staging of Choriocarcinoma

- Rising or plateauing hCG levels after mole evacuation should raise clinical suspicion
- Ultrasound plays a critical role evaluation of rising HCG post molar evacuation
- Pathology distinguishes choriocarcinoma from other forms of GTN
- Check hepatic, thyroid and renal function tests
- FIGO staging and WHO Risk Factor Scoring used in determining prognosis and treatment
 - Low-risk: ≤ 6
 - High-risk: ≥ 7

FIGO Stage	Description
I	Gestational trophoblastic tumors strictly confined to uterine corpus
II	Gestational trophoblastic tumors extending to adnexa or vagina but limited to genital structures
III	Gestational trophoblastic tumors extending to lungs, with or without genital tract involvement
IV	All other metastatic sites

Risk Factors	Risk Factor Scores			
	0	1	2	4
Age (y)	<40	>40
Antecedent pregnancy	Mole	Abortion	Term	...
Interval from index pregnancy (mo)	<4	4-6	7-12	>12
Pretreatment β -hCG level (mIU/mL)	$<10^3$	$>10^3-10^4$	$>10^4-10^5$	$>10^5$
Largest tumor size including uterus (cm)*	...	3-4	≥ 5	...
Site of metastases including uterus*	Lung	Spleen, kidney	Gastrointestinal tract	Brain, liver
Number of metastases identified*	...	1-4	5-8	>8
Previous failed chemotherapy	Single drug	Two or more drugs

Shaaban, Akram M., et al. "Gestational trophoblastic disease: clinical and imaging features." *Radiographics* 37.2 (2017): 681-700.

Management and Treatment of Choriocarcinoma

- Low-risk patients: single chemotherapeutic agent (nearly 100% remission)
 - Either Methotrexate or Actinomycin D
- High-risk patients: EMA-CO (85% remission)
 - Etoposide, methotrexate, actinomycin D, cyclophosphamide, and vincristine
- Selective Hysterectomy may be advisable
- Stage I-III
 - Weekly hCG are indicated until it reaches normal levels for 3 consecutive weeks
 - Monitor of hCG monthly for 1 year after normalization
 - Imaging is not routine
- Stage IV
 - Similar to Stage I-III, but monitor for 24 months
- Contraception for entire interval follow-up period
 - Preference is oral contraceptives

Case Resolution

- Patient underwent an MRI of the brain (due to the presence of lung metastases), which ruled out metastasis to the brain
- Patient is low-risk (WHO 1 based on CXR), so she was started and continues on adjuvant Methotrexate
- hCG was monitored weekly during treatment
 - Her most recent hCGs continue to decline on treatment
- Patient was started on oral contraceptives

References

- Crum, Christopher P., et al. *Diagnostic Gynecologic and Obstetric Pathology E-Book*. Elsevier Health Sciences, 2017.
- Lurain, John R. "Gestational trophoblastic disease I: epidemiology, pathology, clinical presentation and diagnosis of gestational trophoblastic disease, and management of hydatidiform mole." *American journal of obstetrics and gynecology* 203.6 (2010): 531-539.
- Savage, Julia L., et al. "Sonographic diagnosis of partial versus complete molar pregnancy: A reappraisal." *Journal of Clinical Ultrasound* 45.2 (2017): 72-78.
- Shaaban, Akram M., et al. "Gestational trophoblastic disease: clinical and imaging features." *Radiographics* 37.2 (2017): 681-700.
- Sebire, N. J., and M. J. Seckl. "Gestational trophoblastic disease: current management of hydatidiform mole." *Bmj* 337 (2008): a1193.