

AMSER Case of the Month

June 2018

66-year old female status post cardiac surgery



Kristin Day, MS IV LECOM

Jeff Mueller, MD Allegheny Health Network

Division Head, Chest Imaging



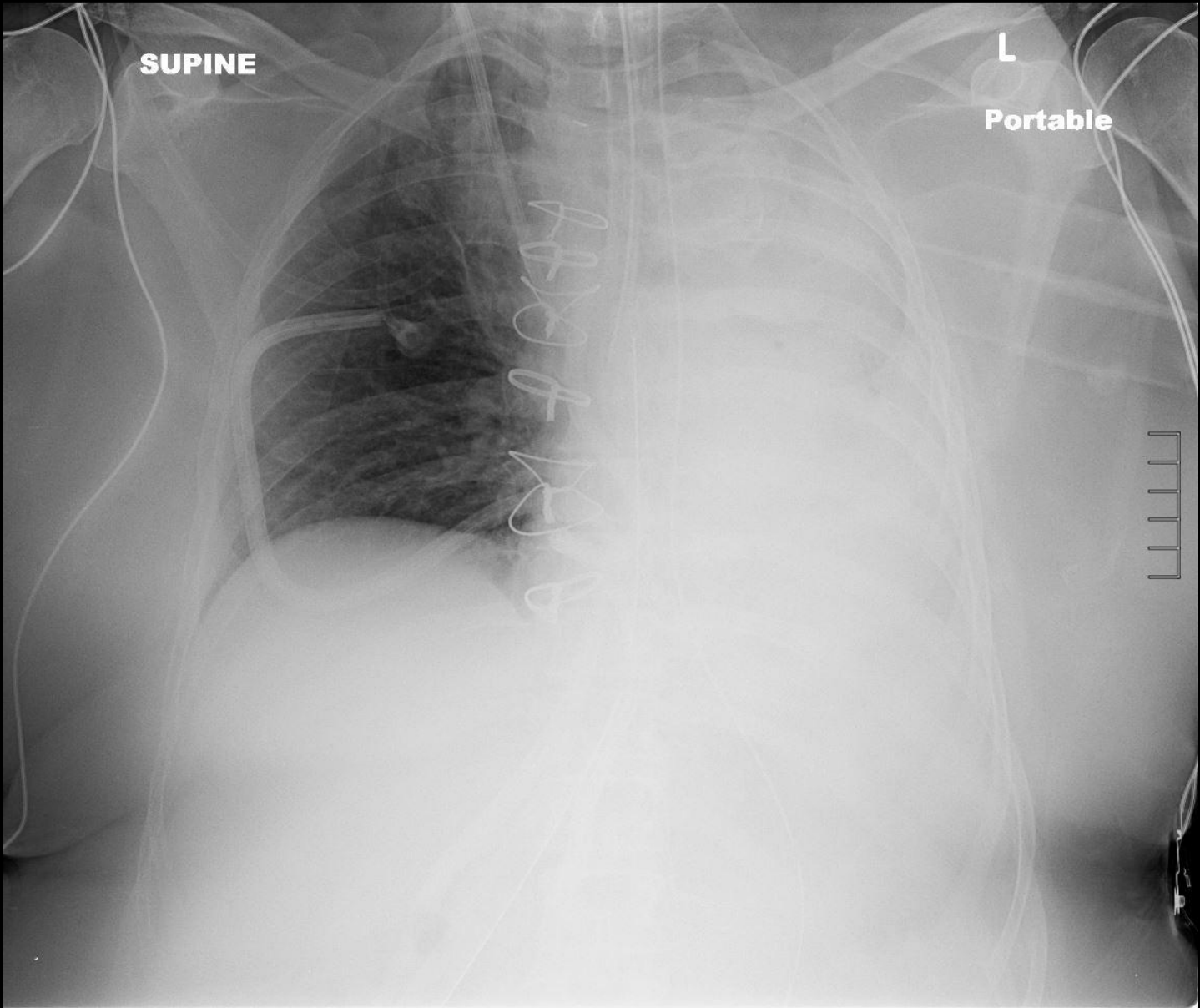
Patient Presentation

- 66-year old female status post cardiac surgery
- Preoperative diagnosis: left atrial myxoma
- Operative procedure:
 - Resection of left atrial myxoma via bilateral approach
 - Closure of atrial septal defect with bovine pericardial patch
- Transferred to the Surgical ICU in stable condition

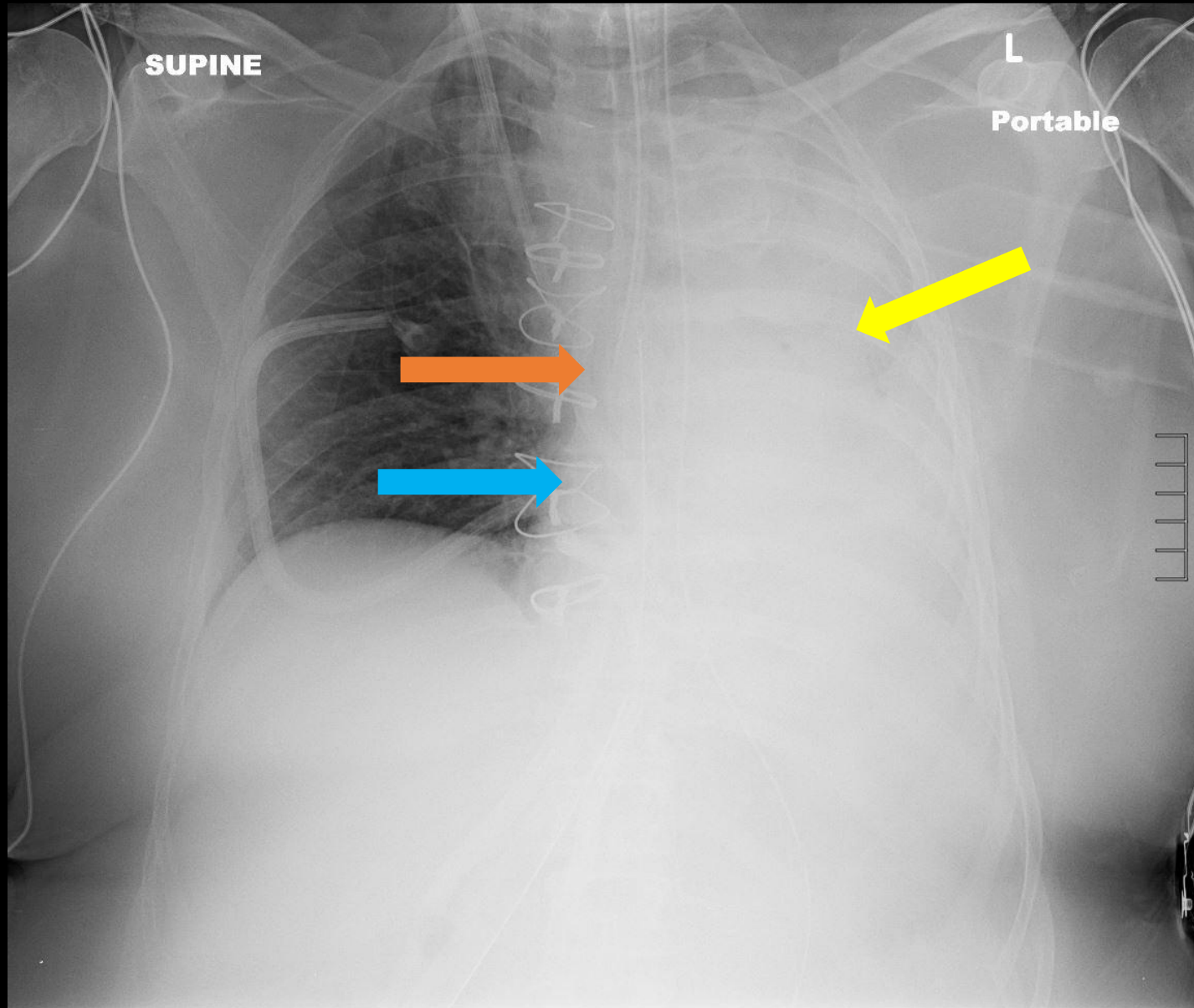
Patient History

- Past medical history:
 - Atrial myxoma, acquired hypothyroidism, hyperglycemia, dyslipidemia, dyspnea on exertion
- Past surgical history:
 - Cardiac catheterization, thyroidectomy, joint replacement

STAT Chest Radiograph 3-4 hours Post Operatively



Findings of Post Operative Chest Radiograph



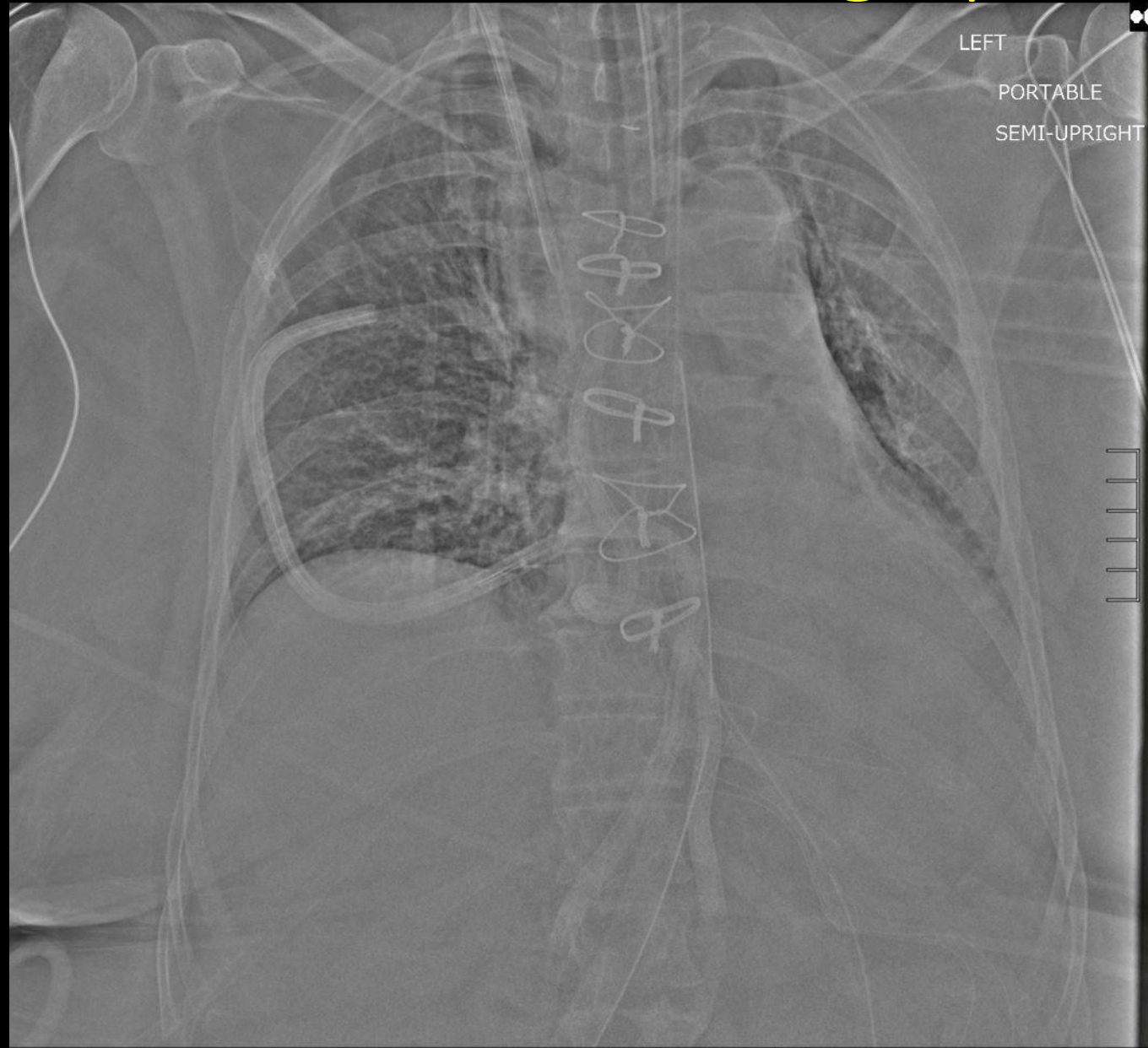
- Left hemithorax is completely opacified (yellow)
- Endotracheal tube (ETT) tip is located in the right main stem bronchus (orange)
- Right heart border (blue) and trachea are shifted to the left

Diagnosis

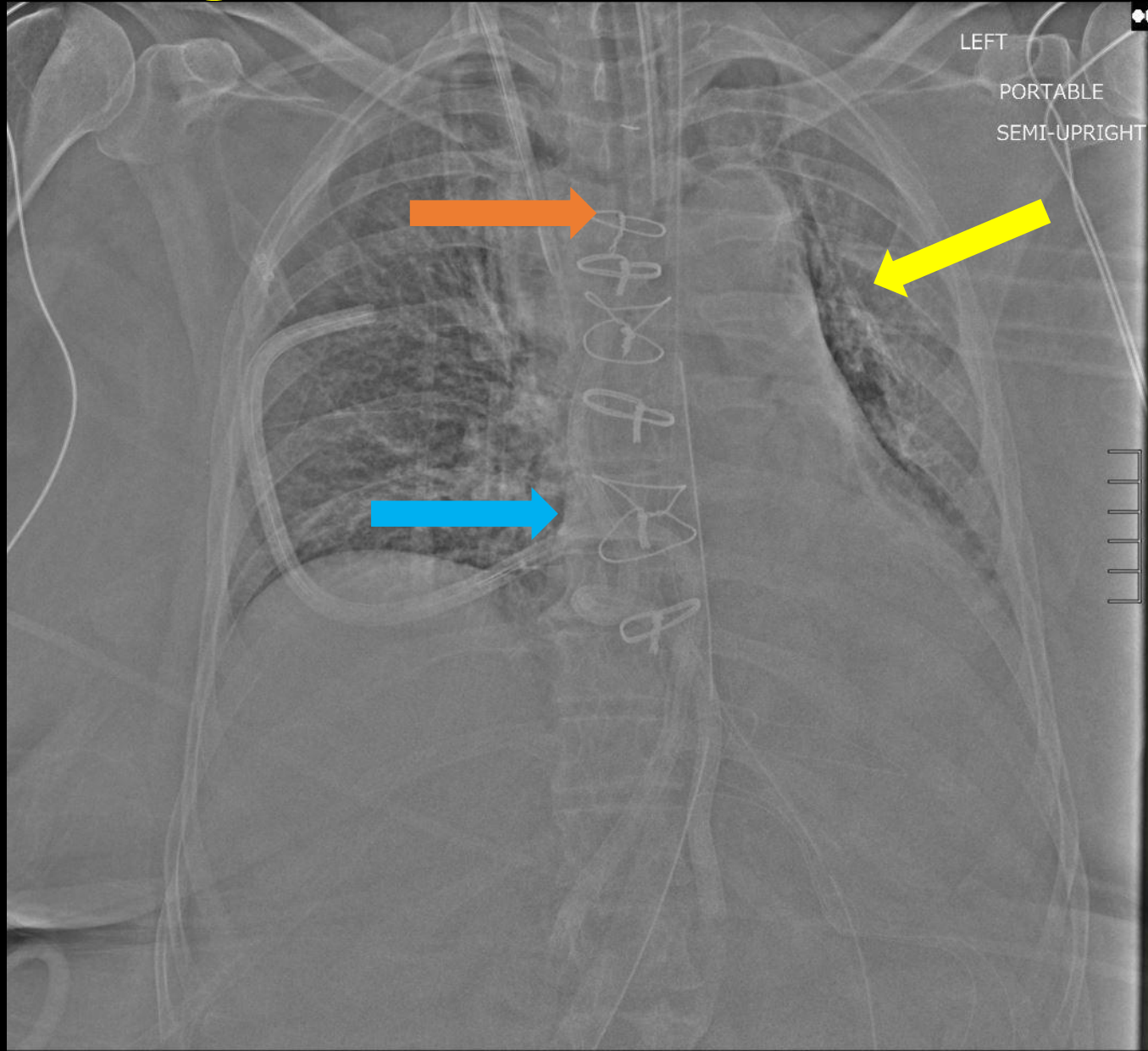
Complete atelectasis of the left lung
secondary to right mainstem ETT intubation

Retract endotracheal tube 6 cm!

Post Retraction Chest Radiograph



Findings of Post Retraction Chest Radiograph



- Improved left upper lobe aeration (yellow) with persistent left lower lobe atelectasis
- Endotracheal tube tip is located at the level of the aortic arch (orange)
- Heart and trachea are still slightly displaced to the left (blue)

Discussion

- Atelectasis of the entire lung
 - Resulting from complete obstruction of the left main bronchus
 - Loss of air volume in the left lung causing collapse of the alveoli
 - Shift of the heart and trachea toward the side of the atelectasis

Discussion

- Correct placement of endotracheal tube
 - The tip should be 3-5cm above the carina
 - Landmark for the ideal position for the ETT is mid trachea, halfway between the larynx and carina—between the clavicular heads
 - Neck flexion and extension can cause 2cm of descent and ascent of the tip, respectively.
 - The tip should be advanced at least 3 cm distal to the level of the vocal cords
- Clinical examination
 - Auscultate the lungs bilaterally to ensure air movement with inhalation and exhalation

Reference

Herring, William. Learning Radiology: Recognizing The Basics, 3rd ed.
Philadelphia: Elsevier, 2016.